

## Case Report

# Talaromycosis in Assam: a case report

Nilakshi Borah\*, Ajanta Sharma, Lahari Saikia

Department of Microbiology, State Cancer Institute, Gauhati Medical College, Guwahati, Assam, India

**Received:** 14 October 2020

**Revised:** 19 November 2020

**Accepted:** 20 November 2020

### \*Correspondence:

Dr. Nilakshi Borah,

E-mail: drnilakshiborah2018@gmail.com

**Copyright:** © the author(s), publisher and licensee Medip Academy. This is an open-access article distributed under the terms of the Creative Commons Attribution Non-Commercial License, which permits unrestricted non-commercial use, distribution, and reproduction in any medium, provided the original work is properly cited.

### ABSTRACT

Talaromycosis is an opportunistic infection caused by a dimorphic fungus, *Talaromyces marneffeii*. We describe here a case of 38 years old HIV seropositive male patient from Assam presented with fever, cough, weight loss and discrete, multiple, umbilicated papules and nodules in face and upper trunk. Differential diagnosis of histoplasmosis, giant molluscum contagiosum and talaromycosis were considered. Histopathological and mycological study of skin biopsy tissue confirmed the diagnosis of talaromycosis. Primary treatment with amphotericin B and itraconazole showed promising results. Early diagnosis and adequate antifungal therapy are imperative to avoid the complications. *Talaromyces* requires further in-depth study with respect to its global distribution, natural history, pathogenesis and the impact of antiretroviral therapy.

**Keywords:** Talaromycosis, *Talaromyces marneffeii*, Dimorphic fungus, HIV, Amphotericin B

## INTRODUCTION

Talaromycosis (formerly known as Penicilliosis) is an opportunistic infection caused by a dimorphic fungus, *Talaromyces marneffeii* (earlier-Penicillium marneffeii). *T. marneffeii* is classified under the class, ascomycetes, genus talaromyces and subgenus beverticillium. It is the only talaromyces species to cause significant human disease.<sup>1</sup> It was identified as a new species by Segratain, who named the fungus Penicillium marneffeii.<sup>2</sup> The infection is endemic in Southeast Asia and Southeastern China. Southeast Asian countries from where cases frequently reported are- Thailand, Vietnam, Laos, Myanmar, Malaysia, Cambodia, Singapore, Indonesia and northeastern India. This fungus was first isolated in 1956 in bamboo rats (*Rhizomys sinensis*) at the Pasteur Institute of Indochina, Vietnam.<sup>3</sup> Four species of bamboo rats have been found to serve as carriers of *T. marneffeii*: *Rhizomys sinensis*, *R. pruinosus*, *R. sumatrensis* and *Cannomys badius* in Southeast Asia.<sup>4</sup> The first spontaneous infection in a human was reported in 1973 in a 61 years old American minister with Hodgkin's disease, who had travelled to South East Asia one year

before.<sup>5</sup> *T. marneffeii* infection was first reported in HIV infected patients in 1988.<sup>6</sup> It ranks third in opportunistic infections behind tuberculosis and cryptococcosis in patients with acquired immunodeficiency syndrome (AIDS).<sup>7</sup> The prevalence of *T. marneffeii* has increased substantially during the past few years. This increased has occurred exclusively among patients infected with HIV in endemic regions as well as in eastern India where the disease was not known before and where bamboo groves abound.<sup>8</sup> Disseminated *Talaromyces marneffeii* infection from Assam was reported for the first time, in 2004.<sup>9</sup> A case of Talaromycosis in immunocompromised patient is being presented here along with an analysis of the available documented reports of *T. marneffeii* infection.

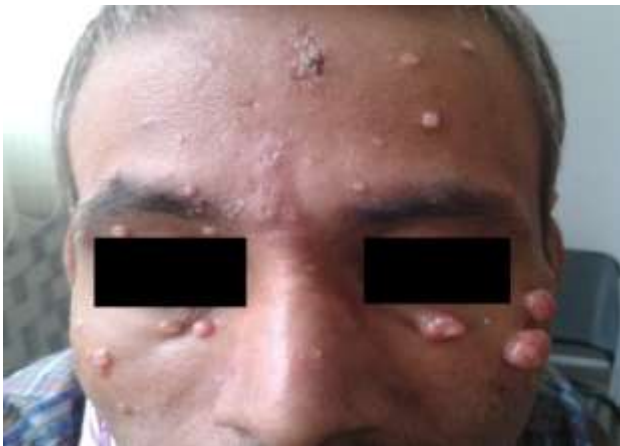## CASE REPORT

A 38-years-old unmarried male, bus driver from Assam, a north-eastern state of India presented to the Department of Dermatology of a tertiary care hospital of Assam, with a 2-month history of multiple discrete umbilicated papular lesions on the face and upper part of his body.

Papules were pearly white in colour and some were excoriated. There was a history of general weakness, weight loss, loss of appetite, chronic cough, and low-grade fever for the last 3 months.

He admitted to having multiple unprotected sexual encounters with multiple women. He gave no history of moving out of Assam.

Examination revealed an anxious man with multiple discrete papules and nodules with umbilication, varying in size (5-20 mm) on the face, neck, chest, back, and proximal upper limbs (Figure 1). Colour of the lesion varies from erythematous to pearly white. He also had oral candidiasis. There was no lymph node enlargement. Cardiovascular, respiratory, neurological, and abdominal examinations were unremarkable. He was diagnosed as HIV reactive as per NACO guidelines and his absolute CD4 count was 48/cmm. The montoux test was negative. The chest radiograph was clear without any evidence suggestive of tuberculosis.



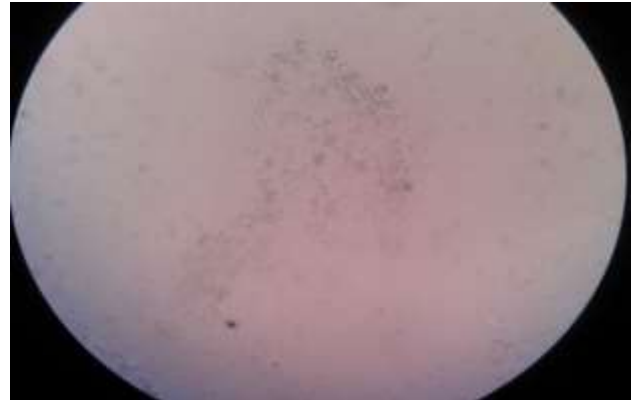
**Figure 1: Multiple lesions on the face showing various morphological patterns like vesicles, crusted umbilicated papules and nodules.**

A differential diagnosis of Talaromycosis, giant molluscum contagiosum and histoplasmosis with underlying human immunodeficiency virus (HIV) infection was made.

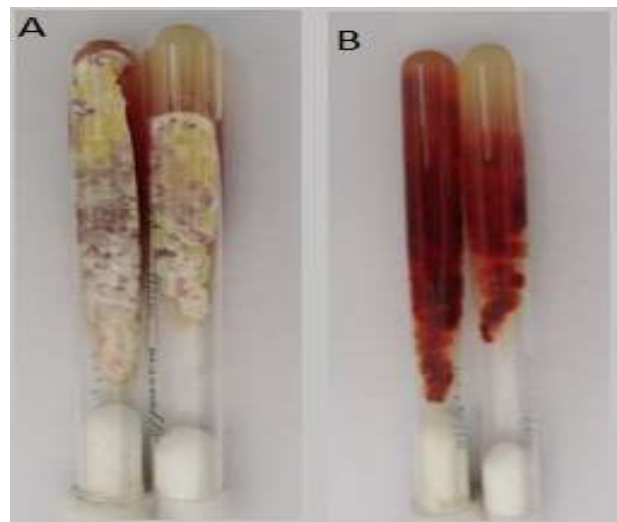
The blood profile showed that he was anemic (hemoglobin of 7.6 g/dl). The erythrocyte sedimentation rate was 30 mm in the first hour. The total white cell count showed increase in neutrophil count (91.1%) and decrease in lymphocyte count (6.3%). Liver function tests showed increased delta bilirubin (0.51 mg/dl), increased AST (75 u/l), low albumin (2.5 g/dl), high globulin (4 g/dl) and low albumin globulin ratio (0.6 g/dl). Platelet count, fasting blood lipids, fasting blood sugar, and renal profile were normal.

Excision biopsy of the lesions was performed and was divided into several (7) small portions. One portion was

processed for giemsa stain, one for KOH mount, one for gram stain and four portions were processed for culture in sabouraud dextrose agar with chloramphenicol (0.05mg/ml) and sabouraud dextrose agar with chloramphenicol (0.05 mg/ml) and cycloheximide (0.5 mg/ml) slants in duplicate. Giemsa stained smears of the biopsied tissue showed numerous intracellular and extracellular oval, elongated or sausage shaped yeast like cells, many dividing by binary fission rather than by a budding process were noted. KOH mount showed oval, elongated or sausage shaped yeast like cells (Figure 2). Gram stain also revealed elongated yeast cells.



**Figure 2: Multiple small fungal elements in yeast form (KOH×40).**

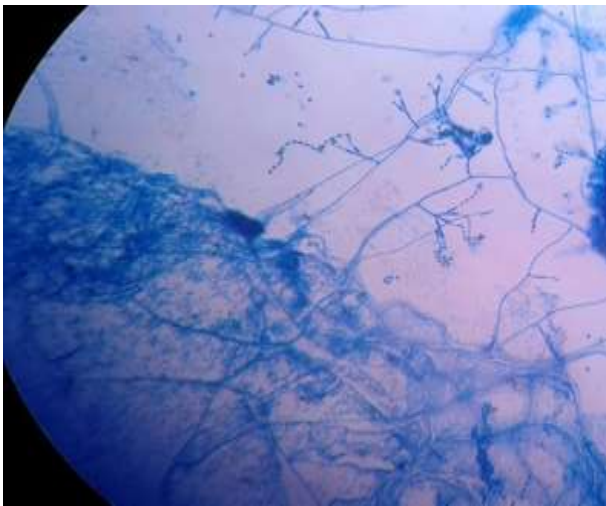


**Figure 3: Granular colony of *T. marneffei* (A) Obverse, (B) Reverse with a characteristic red diffusible pigment on Sabouraud's dextrose agar with chloramphenicol (0.05 mg/ml) at 25°C**

A portion of it was cultured in sabouraud dextrose agar with chloramphenicol (0.05 mg/ml) and sabouraud dextrose agar with chloramphenicol (0.05 mg/ml) and cycloheximide (0.5 mg/ml) slants in duplicate. One set of cultures were incubated at 25°C and other set was incubated at 37°C. The cultures were observed every 2 days. There was growth in the SDA tubes containing

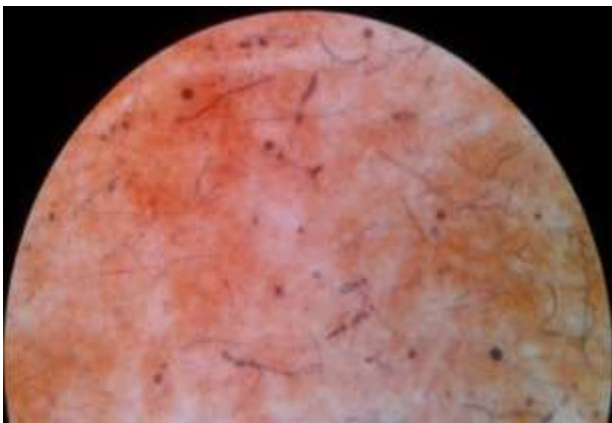Sabouraud Dextrose agar with chloramphenicol (0.05 mg/ml) and the growth was inhibited by cycloheximide. Colonies at 25°C, were velvety to moist, glabrous, initially white in colour with a characteristic intense wine-red pigment that diffused into the medium within 7 days of incubation (Figure 3). Colonies at 37°C were moist, yeast like, white to brownish white.

Microscopically, mycelial form cultures showed that the hyphae were hyaline, septate, and branched and bore lateral and terminal conidiophores. The conidiophores consisted of basal stripes, bearing terminal verticils of three to five metulae, bearing four to seven phialides in a verticillate manner. The phialides produced basipetal chains of smooth, spherical to ellipsoidal conidia often showing prominent disjunctors (Figure 4).



**Figure 4: Brush like conidiophores, metulae, phialides and conidia from the growth at 25°C (LCB×40).**

Microscopically, the cultures incubated at 37°C showed a mixture of separate, branching hyphae and many ovate to cylindrical yeast like cells dividing by septation (Figure 5).



**Figure 5: Numerous septate yeast cells and arthroconidia from the growth at 37°C (gram staining×400).**

Based on its macroscopic and microscopic morphology, the presence of a characteristic red diffusible pigment, and the dimorphic nature of the isolate, it was identified as *Talaromyces marneffeii*.

He was immediately started with intravenous amphotericin B (0.6 mg/kg) for 2 weeks followed by oral itraconazole 400 mg daily in two divided doses for 10 weeks, and clotrimazole mouth paint for the oral thrush. Highly active antiretroviral therapy (HAART) was started after 2 weeks of initiation of antifungal therapy.

The improvement was evident by disappearance of skin lesions after 2 weeks, subsidence of fever after 1 week and weight gain.

## DISCUSSION

*Talaromyces marneffeii* infection has been reported to be the third most common illness that defines AIDS in South east Asia.<sup>10</sup> Disseminated infection usually presents with fever, weight loss, anaemia, generalized lymphadenopathy, hepatosplenomegaly, cough and may rapidly progress to death if not treated.<sup>11</sup> Skin lesions commonly occur on the face, upper trunk and extremities. Papular skin lesions with central necrotic umbilication occur more commonly in HIV infected patients.<sup>12</sup> The typical cutaneous papules with central necrotic umbilication may be present in about 70% of patients.<sup>13</sup> *T. marneffeii* infection occurs late in the course of HIV infection, when CD4 lymphocyte counts is <100 cells/cmm.<sup>12</sup> It is common to have signs and symptoms reflecting involvement of reticuloendothelial system including anaemia, hepatosplenomegaly and lymphadenopathy. Respiratory involvement is often present, with productive cough, dyspnea and haemoptysis. Chest X-ray may show diffuse reticular infiltration, localized alveolar infiltrates or cavitary lesion.<sup>14</sup> Since talaromycosis is usually seen in advanced stage of HIV infection, 55 to 77% of cases may have other concurrent opportunistic infections such as tuberculosis, disseminated herpes zoster, *Pneumocystis jirovecii* pneumonia, *Cryptococcosis*, *toxoplasmosis* and should be watched out for.<sup>13,15</sup> The mode of infection is considered to be due to inhalation of conidia reaching lungs and subsequent disseminations to the reticuloendothelial system when the host experiences immunosuppression.<sup>16</sup> While exposure to soil has been suggested as a risk factor, another study found that *T. marneffeii* is not present in soil except around animal burrows.<sup>17,18</sup> It remains unclear whether rats are involved in transmitting the organism to humans, or whether both humans and rats are infected from a common but still unidentified source.<sup>19</sup> There is no study indicating man to man transmission of this infection.<sup>3</sup> The incubation period for *T. marneffeii* is 1-3 weeks in patients with acute disease. In addition, latent *T. marneffeii* infection can occur, with disease reactivation at any time in immunocompromised hosts.<sup>20</sup> Isolation of *T. marneffeii* remains the gold standard for diagnosis. Among all the

clinical specimens studied, the bone marrow gives the highest yield for culture, approaching 100%. This is followed by skin biopsy (90%) and blood culture

(76%).<sup>13</sup> There is no standardized technique or interpretation criteria for antifungal susceptibility testing for dimorphic fungus.

**Table 1: Worldwide distribution of clinical infections caused by *T. marneffeii*.**

Table References	Year	Place	Sites/type of infection	Immune status	Treatment*	Outcome
Devi et al <sup>26</sup>	2020	Manipur	Skin lesions	Immunocompromised (HIV)	ITRA+ART	Not known
Devi et al <sup>26</sup>	2020	Manipur	Skin lesions	Immunocompromised (HIV)	AMB+ITRA+ART	Cured
Devi et al <sup>26</sup>	2020	Manipur	Skin lesions+ pulmonary T.B	Immunocompromised (HIV)	ITRA+ART+ATD	Not known
Gorai et al <sup>27</sup>	2019	Assam	Skin lesions	Immunocompromised (HIV)	AMB+ART	Cured
Sarkar et al <sup>28</sup>	2019	Assam	Skin lesions+oral thrush	Immunocompromised (HIV)	AMB+ART	Not known
Sarkar et al <sup>28</sup>	2019	Assam	Skinlesions+pulmonary T.B	Immunocompromised (HIV)	-	Not known
Wongkamhla et al <sup>29</sup>	2019	Thailand	Oro-pharyngo-laryngitis	Immunocompetent	AMB+ITRA	Cured
Lalnunhlua et al <sup>30</sup>	2017	Manipur	Hoarseness+ Skin lesions	Immunocompromised (HIV)	AMB+ITRA	Cured
Saikia et al <sup>31</sup>	2010	Assam	Skin lesions	Immunocompromised (HIV)	-	Not known
Soodet al <sup>32</sup>	2010	Mizoram	Disseminated	Immunocompromised (HIV)	AMB+ITRA+ART	Died
George et al <sup>33</sup>	2008	Meghalaya	Acute abdomen (Disseminated)	Immunocompromised (HIV)	AMB+ITRA	Not known
Sharma et al <sup>34</sup>	2007	Manipur	Skin lesions	Immunocompromised (HIV)	Fluconazole	Cured
Chaiwun et al <sup>35</sup>	2002	Thailand	Skin lesions Lymphadenopathy	Immunocompromised (HIV)	AFT (Name not mentioned)	Cured
Chaiwun et al <sup>35</sup>	2002	Thailand	Mesenteric lymphadenopathy	Immunocompromised (HIV)	AFT (Name not mentioned)	Cured
Singh et al <sup>36</sup>	1999	Manipur	Skin lesions	Immunocompromised (HIV)	-	Died
Singh et al <sup>36</sup>	1999	Manipur	Skin lesions	Immunocompromised (HIV)	ITRA	Cured
Singh et al <sup>36</sup>	1999	Manipur	Skinlesions+cervical lymphadenitis+ PCP +Oral thrush	Immunocompromised (HIV)	ITRA	Cured
Singh et al <sup>36</sup>	1999	Manipur	Skin lesions+upper abdominal lump+cervical lymphadenopathy	Immunocompromised (HIV)	ITRA	Cured

\*AMB: Amphotericin B, ITRA: Itraconazole, ART: Antiretroviral treatment, ATD: Antitubercular drug

The result of susceptibility testing in dimorphic fungus is influenced by the method, incubation duration, incubation condition and medium used. The inhibitory level of the same drug can be different against the yeast or the mycelial form of the same fungal isolate and the correlation between in vitro testing and in vivo efficacy is largely unknown.<sup>21-23</sup> Treatment with amphotericin B (0.6 mg/kg) for 2 weeks followed by oral Itraconazole 400mg daily for 10 weeks has resulted in excellent response rates. Voriconazole can be used as alternative as it has

been found to be highly active in vitro against *T. marneffeii* and may thus provide another option for treatment or prophylaxis.<sup>24</sup> After initial treatment the patient should be given itraconazole 200 mg/day, as secondary prophylaxis for life, if HAART cannot be offered. The mortality rate of untreated talaromycosis is 100%.<sup>25</sup> Any delay in the initiation of antifungal therapy is associated with poor outcome, whereas the therapeutic response is good with early institution of treatment.



Table 1 shows a worldwide distribution of clinical infections caused by *T. marneffei*.

## CONCLUSION

As *Talaromyces marneffei* is an emerging pathogen, a high index of suspicion is required for making an early diagnosis, for treatment of such rare cases, in areas which have geographical proximity to South eastern Asia, north-eastern India and Bangladesh. Establishing a correct diagnosis in a timely manner is important since effective treatment is available and manifestations and sequelae of the disease can be severe. It is now considered as one of the significant imported mycoses as it is increasingly being reported from non-native persons from outside Southeast Asia and among individuals residing in non-endemic areas, who have significant history of travel to Southeast Asia. *Talaromyces* requires further in-depth study with respect to its global distribution, natural history, pathogenesis and the impact of antiretroviral therapy.

*Funding: No funding sources*

*Conflict of interest: None declared*

*Ethical approval: Not required*

## REFERENCES

- Bradsher RW. Geographic, travel and occupational fungal infections. In: Anaissie EJ, McGinnis MR, Pfaller MA, editors. *Clinical Mycology*. 1st ed. New York: Churchill Livingstone. 2003:583-7.
- Viviani MA, Tortorano AM. *Penicillium marneffei*. In: Collier L, Balows A, Sussman M, editors. *Topley & Wilson's Microbiology and Microbial Infections*. 9th ed. London: Arnold; 1998:409-18.
- Chander J. *Talaromyces*. In: *Textbook of Medical Mycology*, 4th edition. New Delhi: Jaypee Publishers; 2018:506-23.
- Sirisanthana T, Supparatpinyo K. Epidemiology and management of penicilliosis in human immunodeficiency virus-infected patients. *Int J Infect Dis*. 1998;3(1):48-53
- DiSalvo AF, Fickling AM, Ajello L. Infection caused by *Penicillium marneffei*: description of first natural infection in man. *Am J Clin Pathol*. 1973;59:259-63
- Piehl MR, Kaplan RL, Haber MH. Disseminated penicilliosis in a patient with acquired immunodeficiency syndrome. *Arch Pathol Lab Med*. 1988;112:1262-4
- Nittayananta W. Penicilliosis marneffei: Another AIDS defining illness in Southeast Asia. *Oral Dis*. 1999;286-93
- Ranjana KH, Priyokumar K, Singh TJ, Gupta CC, Sharmila L, Singh PN, et al. Disseminated *Penicillium marneffei* infection among HIV – infected patients in Manipur State, India. *J Infect*. 2002;45:268-71
- Varghese GM, Pise G, Michael SJ, Jacob M, George R. Disseminated *Penicillium marneffei* infection in a human immunodeficiency virus-infected individual. *J Postgrad Med*. 2004;50:235-6
- Cooper CR, McGinnis MR. Pathology of *Penicillium marneffei*. An emerging acquired immunodeficiency syndrome related pathogen. *Arch Pathol Lab Med*. 1997;121:798-804
- Srisanthana T. Infection due to *Penicillium marneffei*. In: Warrell DA, Cox TM, Firth JD, editors. *Oxford Textbook of Medicine*. 4th ed. New York: Oxford University Press; 2003:712-3.
- Devi SB, Devi TS, Ningshen R, Devi Kh R, Singh TB, Singh NB. *Penicillium marneffei*, an emerging AIDS related pathogen- a RIMS study. *J Ind Med Assoc*. 2009;107(4):208-10
- Supparatpinyo K, Khamwan C, Baosoung V, Nelson KE, Sirisanthana T. Disseminated *Penicillium marneffei* infection in Southeast Asia. *Lancet*. 1994;344:110-3
- Deesomchok A, Tanprawate S. A 12 case series of *Penicillium marneffei* pneumonia. *J Medic Assoc Thai*. 2006;89(4):441-7
- Wu TC, Chan JWM, Ng CK, Tsang DNC, Lee M P, Li PCK. Clinical presentations and outcomes of *Penicillium marneffei* infections: a series from 1994 to 2004. *Ho Ko Medic J*. 2008;14(2):103-9
- Kantipong P, Panich V, Pongsurachet V, Watt G. Hepatic penicilliosis in patients without skin lesions. *Clin Infect Dis*. 1998;26(5):1215-7
- Chariyalertsak S, Sirisanthana T, Supparatpinyo K, Praparattanapan J, Nelson K. Case-control study of risk factors for *Penicillium marneffei* infection in human immunodeficiency virus infected patients in northern Thailand. *Clin Infect Dis*. 1997;24:1080-6
- Chariyalertsak S, Vanittanakom P, Nelson K, Sirisanthana T, Vanittanakom N. *Rhizomys sumatrensis* and *Cannomys badius*, new natural animal hosts of *Penicillium marneffei*. *J Med Vet Mycol*. 1996;34:105-10
- Deng Z, Ribas J, Gibson D, Connor D. Infections caused by *Penicillium marneffei* in China and Southeast Asia: review of eighteen published cases and report of four more Chinese cases. *Rev Infect Dis*. 1988;10:640-52.
- Chastain DB, Henaio-Martinez AF, Franco-Paredes C. Opportunistic invasive mycoses in AIDS: cryptococcosis, histoplasmosis, coccidioidomycosis, and talaromyces. *Curr Infect Dis Rep*. 2017;19:36.
- Boon-Long J, Mekha N, Poonwan N. In vitro antifungal activity of the new triazole DO870 against *Penicillium marneffei* compared with that of amphotericin B, fluconazole, itraconazole, miconazole and flucytosine. *Mycoses*. 1996;39(11-12):453-56
- Sekhona AS, Garg AK, Padhye AA, Hamir Z. In vitro susceptibility of mycelial and yeast forms of *Penicillium marneffei* to amphotericin B, fluconazole, 5-fluorocytosine and itraconazole. *Europ J Epidemiol*. 1993;9(5):553-8.

23. Nakai T, Uno J, Ikeda F, Tawara S, Nishimura K, Miyaji M. In vitro antifungal activity of micafungin (FK463) against dimorphic fungi: comparison of yeast-like and mycelial forms. *Antimicrob Agen Chemother.* 2003;47(4):1376-81
24. Radford SA, Johnson EM, Warnock DW. In vitro studies of activity of Voriconazole, a new triazole antifungal agent, against emerging and less-common mold pathogens. *Antimicrob Agents Chemther* 1997;41:841-3
25. Supparatpinyo K, Nelson KE, Merz WG, Breslin BJ, Cooper CR, Kamwan C, et al. Response to antifungal therapy by human immunodeficiency virus infected patients with disseminated *Penicillium marneffei* infections and in vitro susceptibilities of isolates from clinical specimens. *Antimicrod Agents Chemother.* 1993;37(11):2407-11
26. Devi B, Sana S, Meka B, Raj B. Disseminated talaromycosis: an AIDS defining fungal infection. *Int J Res Dermatol.* 2020;6:676-9
27. Gorai S, Saha M, Madhab V, Mitra S. Talaromycosis (*Penicilliosis*): A rare, opportunistic systemic fungal infection. *Ind J Dermatol.* 2019;64:331-3
28. Sarkar S, Saha A, Shukla S. Two sporadic cases of *Penicillium marneffei* infection associated with human immunodeficiency virus infection from West Bengal: A word of caution. *Indian J Sex Transm Dis AIDS.* 2019;40(2):180-2
29. Wongkamhla T, Chongtrakool P, Jitmuang A. A case report of *Talaromyces marneffei* Oropharyngo-laryngitis: a rare manifestation of Talaromycosis. *Bio Med Centr Infect Disea.* 2019;19:1034
30. Lalnunhlua HC, Devi SB, Chanu KJ, Singh KB. Hoarseness due to *Penicillium marneffei* infection- an unusual presentation. *Int J Med and Dent Sci.* 2017;6(1):1426-9.
31. Saikia L, Nath R, Mahanta J. *Penicillium marneffei* infection in Assam. *Indian J Dermatol Venerol Leprol.* 2010;76:75-6.
32. Sood N, Gugnani HC. Disseminated *Penicillium marneffei* infection in a Myanmar refugee from Mizoram state. *Indian J of Pathol and Microbiol.* 2010;53(2):361-3.
33. George IA, Sudarsan TD, Pulimood AB, Mathews MS. Acute abdomen: an unusual presentation of disseminated *Penicillium marneffei* infection. *Ind J Medic Microbiol.* 2008;26(2):180-95.
34. Sharma A, Hazarika NK, Barua P. *Penicillium marneffei* infection in a HIV infected child. *Ind J Med Res.* 2007;126:580-2.
35. Chaiwun B, Khunamornpong S, Sirivanichai C, Rangdaeng S, Supparatpinyo K, Settakorn J et al. Lymphadenopathy due to *Penicillium marneffei* infection: Diagnosis by Fine needle aspiration cytology. *Mod Pathol.* 2002;15(9):939-43.
36. Singh PN, Ranjana K, Singh I, Singh KP, Sharma SS et al. Indigenous Disseminated *Penicillium marneffei* Infection in the State of Manipur, India: Report of Four Autochthonous cases. *J Clin Microbiol.* 1999;37(8):2699-702.

**Cite this article as:** Borah N, Sharma A, Saikia L. Talaromycosis in Assam: a case report. *Int J Res Med Sci* 2020;8:4503-8.