

Original Research Article

Outcome of management of intracapsular fracture neck of femur in young adult patients

Sakib Arfee¹, Asma Jabeen^{2*}, Akib Arfee³, Adnan Aadil Arfee⁴

¹Department of Orthopedics, GMC, Jammu, Jammu and Kashmir, India

²Department of Ophthalmology, GMC, Jammu, Jammu and Kashmir, India

³Department of Radiodiagnosis and Imaging, GMC, Srinagar, Jammu and Kashmir, India

⁴Department of Surgery, GMC, Jammu, Jammu and Kashmir, India

Received: 15 November 2020

Accepted: 21 November 2020

*Correspondence:

Dr. Asma Jabeen,

E-mail: drasma.17@gmail.com

Copyright: © the author(s), publisher and licensee Medip Academy. This is an open-access article distributed under the terms of the Creative Commons Attribution Non-Commercial License, which permits unrestricted non-commercial use, distribution, and reproduction in any medium, provided the original work is properly cited.

ABSTRACT

Background: Almost four centuries back fracture neck of femur was described, but till today this fracture is unsolved, though situation has largely improved from the days of Sir Astley Cooper, who had said “I have never met one in whom union had taken place”. High incidence of complications with this fracture even in modern day show that we still have not found way to treat this fracture appropriately and its treatment remains a challenging problem. The objective of the study was to assess the final outcome of management of intracapsular fracture neck of femur in young adult patients after internal fixation.

Methods: This study has been conducted at Orthopedic Department of Government Medical College and hospital, Jammu from 2018 to 2020. 30 young adult patients with fractures neck of femur treated with CCS (27 patients) and DHS (3 patients) after taking informed consent were selected for the study.

Results: 30 young adult patients in age group of 18-60 years, constituted this study. 27 patients were treated with closed reduction and internal fixation with CCS (group A) and 3 patients were treated with DHS (group B). 3 patients were lost to the follow up, all of them from group A.

Conclusions: DHS appears to be more forgiving implant than CCS in fracture neck of femur in young adult patients. However number in this group is very small and hence larger studies are needed. In fixation with CCS anatomical reduction of fracture, proper screw placement is the most important criterion for achieving better results.

Keywords: Neck of femur fracture, Young adults, Management and outcome

INTRODUCTION

Almost four centuries back fracture neck of femur was described, but till today this fracture is unsolved, though situation has largely improved from the days of Sir Astley Cooper, who had said “I have never met one in whom union had taken place”.¹ The high incidence of complications associated with this fracture even in these days of modern surgery show that we still have not found

way to treat this fracture appropriately and the treatment of femoral neck fracture remains a challenging problem.²

High energy trauma is the usual cause of femoral neck fractures in young patients and often are associated with high rates of avascular necrosis and nonunion.³ An important part of rationale for prompt treatment of the fracture is preservation of the blood supply to the femoral head which is critical for a satisfactory long-term result.

The fracture is regarded as an injury to the bone's blood supply.⁴ The degree of vascular compromise is thought to directly correlate with the displacement of the fracture which affects fracture union and leading to complications. Hence intracapsular fracture neck of femur is regarded as an orthopedic emergency and needs to be anatomically reduced with rigid internal fixation which is believed to improve the circulation of femoral head and decrease the non-union and avascular necrosis.⁵

Intracapsular fracture neck of femur is less common in young adults than old but increase in number of high energy trauma result in more frequent encounters by orthopedic surgeons. Compressive loads on femoral neck during a fall are unbalanced due to stress resisting muscular system failure on lateral side, a large quantum of energy acts on proximal femur resulting in fracture. Energy dissipation mechanism doesn't have chance to act, when hip is impacted directly. A direct blow to the trochanter and with lateral rotation and abduction of leg causes the femoral neck to twist. The femoral head remains firmly fixed by iliofemoral ligament and anterior capsule while the neck rotates posteriorly. The posterior cortex impinges over the acetabulum and buckles under the force generated. Tensile and compressive forces act on anterior and posterior cortex of neck of femur respectively, causing comminution over posterior cortex.

Despite numerous technical advancements the ultimate aim has remained elusive. During 1950s surgeons prompted replacement of femoral head with an artificial head because of poor results, but now the consensus has developed in preserving patients own head, even at the cost of second surgery if warranted.⁶

The present study is undertaken keeping in mind the increasing high velocity injury and incidence of the fracture. This study is only a small step to solve the big problem with means and methods easily available.

Objective of this study is to analyze the various parameters and final outcome of management of intracapsular fracture neck of femur in young adult patients after internal fixation in our setup.

METHODS

This study has been conducted at Orthopedic Department of Government Medical College and hospital, Jammu during the period from 2018 to 2020.

After the approval by the Institutional ethics committee 30 young adult patients with fractures neck of femur treated with CCS (27 patients) and DHS (3 patients) after taking informed consent were selected for the study, of which 3 patients were lost to the follow-up.

Hence the total number of patients included in the study was 27 patients.

The follow up period was 1 year, Patients were followed up on regular basis at 2 weeks, 6 weeks, 3 months and 3 monthly till 1 year. Functional outcome was evaluated on the basis of Harris Hip scoring. MS excel was used as statistics software to perform all the statistical analysis in this study.

Inclusion criteria include the patients suffering from post-traumatic intracapsular fracture neck of femur who has given their consent for surgery and patients in the age group of 18 to 60 years. However, pathological fractures, pediatric fractures (before physal closure) and elderly patients age >60 years were excluded from this study.

This study is an observational study with both prospective and retrospective data analysis of patients operated by different surgeons in same hospital setup.

RESULTS

30 young adult patients in age group of 18-60 years, constituted this study. 27 patients were treated with closed reduction and internal fixation with AO cannulated cancellous screws (group A) and 3 patients were treated with closed reduction and internal fixation with dynamic hip screw with side plate (group B). 3 patients were lost to the follow up, all of them from group A.

Table 1: Age distribution.

Age (years)	18-20	21-25	26-30	31-35	36-40	41-45	46-50	51-55	56-60
Male	-	-	2	-	5	10	2	1	1
Female	-	-	-	2	-	-	3	-	1

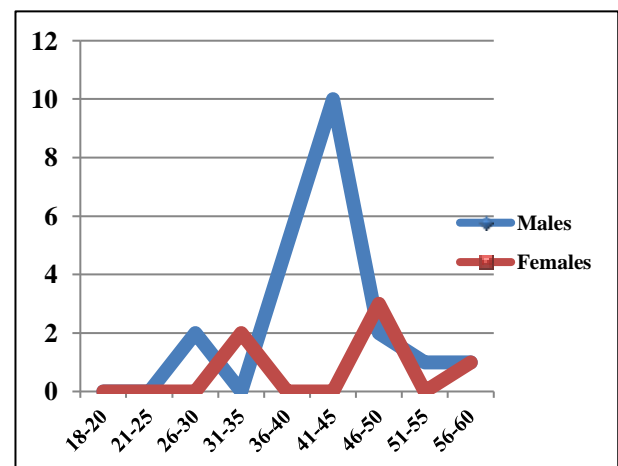


Figure 1: Age distribution.

In remaining 27 cases 21 were males most of them in age group of 41-45 years and 6 were females with 46-50 years age group predominance. Average follow up was 12 months. Union occurred in 91.66% of group A patients

with non-union in 8.33% cases. All of the fractures fixed using DHS showed good results while 52% showed fair and 4% patients showed poor results with CCS fixation. Most of the patients were operated upon within 1 week with average of 2.63 days; our study showed that delay in treatment increases the rate of complications with incidence of avascular necrosis is 12.5 % in CCS group and 0% in DHS group.

Group B patients presented with 100% good results without any complications so far.

Table 2: Garden staging.

Type	Number	Percentage
I	2	7.41
II	1	3.7
III	18	66.67
IV	6	22.22

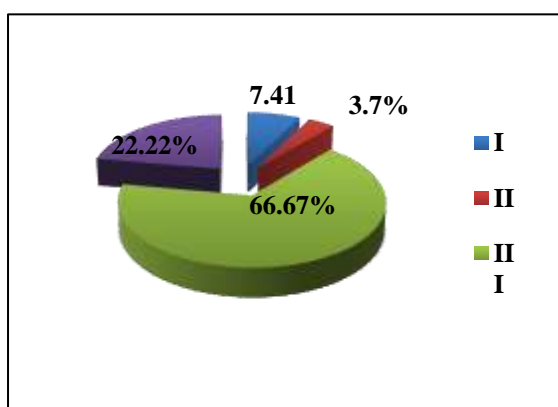


Figure 2: Garden staging.

DISCUSSION

Fracture neck of femur has to be fixed in anatomical position in this study using CCS or DHS, no specific criterion was taken into consideration for selection of implant in this study. The present study showed that in CCS screw positioning was an important factor while side or sex does not affect the final outcome. According to Kaplan et al physiological age rather than the chronological age is more important in deciding the modality of treatment. The quality of bone decides the strength of the implant and rate of cutout or failure.⁷

In our study DHS was found to give superior results than CCS fixation in femoral neck fractures. All of the fractures fixed using DHS showed good results while 52% showed fair and 4% patients showed poor results with CCS fixation. The present study is consistent with the study of Lakhani et al which showed excellent results in only 25.8% of CCS cases and 61.3% of SHS cases.⁸ Singh et al in their study concluded that SHS is a better implant than CC screws in management of fracture neck femur in young adults in pauwels type II and III in terms of functional

outcome but complication rate does not depend on the implant selection.⁹

In the present study it is observed that delay in treatment increases the complications which is already advised by Swiontoskwi that this fracture should be treated earliest to reduce the rate of complications.¹⁰

CONCLUSION

DHS with side plate even without de-rotation screw appears to be more forgiving implant than CCS in fracture neck of femur in young adult patients. However, number in this group is very small and hence larger studies are needed. In fixation with CCS anatomical reduction of fracture, proper screw placement, fracture comminution and bone stock is the most important criterion for achieving better results. In our study lack of anatomical reduction and incorrect screw placement was perhaps the main cause of failure.

Funding: No funding sources

Conflict of interest: None declared

Ethical approval: The study was approved by the Institutional Ethics Committee

REFERENCES

- Dickson, James A. The unsolved fracture. *Journal of Bone and Joint Surgery*. 1953;4:805-22.
- Audekercke, Van R, Martens M, Mulier JC, Stuyck J. Experimental study on internal fixation of femoral neck fractures. *Clinical orthopaedics and related research*. 1979;141:203-15.
- Eisler J, Cornwall R, Strauss E, Koval K, Siu A, Gilbert M. Outcomes of elderly patients with nondisplaced femoral neck fractures. *Clin Orthop*. 2002;399:52-58.
- Luice RS, Fuller, Stephen, Burdick DC, Johnston RM. Early prediction of avascular necrosis of the femoral head following femoral neck fractures. *Clinical Orthopaedics*. 1981;16:207-14.
- Ross K Leighton. Fractures of the Neck of Femur. In: Rockwood and Green's Fractures in Adults. Bucholz RW, Heckman JD, Court-brown CM, 6th ed. Philadelphia: Lippincott Williams and Wilkins 2006;2:1753-92.
- Coleman, Sherman S, Comperi, Clinton L. Femoral neck fracture. Pathogenesis of avascular necrosis, non-union and late degenerative changes. 1957;39B:247-64.
- Kaplan, Akesen B, Demirag B, Bilgen S, Durak K. Comparative results of percutaneous cannulated screws, dynamic compression type plate and screw for the treatment of femoral neck fractures. *Turkish Journal of Trauma and Emergency Surgery*. 2012;18(1):65-70.
- Lakhani AA, Mahajan N, Sonawane DV. A Comparative Study of the Management Of Fracture Neck Femur By Dynamic Hip Compression Screw

- With Derotation Screw Versus Three Cancellous Screws. *Journal of Medical Thesis.* 2014;2(3):5-8.
9. Singh M, Sonkar D, Verma R, Shukla J, Gaur S. Comparison of the functional outcome of DHS versus CCS in Pauwels type II and III fracture neck femur in young adults. *International journal of orthopedics sciences.* 2017;3(2):745-49.
10. Swiontkowski MF. Intracapsular fractures of the hip. *J Bone Joint Surg Am.* 1994;76(1):129-38.

Cite this article as: Arfee S, Jabeen A, Arfee A, Arfee AA. Outcome of management of intracapsular fracture neck of femur in young adult patients. *Int J Res Med Sci* 2020;8:4456-9.