

Original Research Article

Histopathological spectrum of salivary gland lesions - in a tertiary care centre

Gomathi Srinivasan, Francis Asir Joseph J.*, Shanmugam Kaliyaperumal, Arunalatha Ponnaiah

Department of Pathology, Stanley Medical College, Chennai, Tamil Nadu, India

Received: 09 December 2020

Revised: 14 December 2020

Accepted: 15 December 2020

***Correspondence:**

Dr. Francis Asir Joseph J.,

E-mail: francisasirjoseph@gmail.com

Copyright: © the author(s), publisher and licensee Medip Academy. This is an open-access article distributed under the terms of the Creative Commons Attribution Non-Commercial License, which permits unrestricted non-commercial use, distribution, and reproduction in any medium, provided the original work is properly cited.

ABSTRACT

Background: Histopathology is the most important means in diagnosis of salivary gland lesions. The objective of this study is, to study occurrence of salivary lesions during a period of one year from January 2019 to December 2019, to study age, sex and site distribution of various salivary gland lesions, to study histo-morphological aspect of these lesions.

Methods: Surgically resected salivary gland specimens received at Department of Pathology, Government Stanley Medical College, Chennai were subjected to histopathological examination. Specimens were fixed in 10% neutral buffered formalin, processed, embedded, sections cut and stained with hematoxylin and eosin stain.

Results: There were a total of 30 salivary gland specimens. Out of thirty, 25 were neoplastic and 5 were non-neoplastic. Pleomorphic adenoma was the commonest of all benign tumors. Mucoepidermoid carcinoma was the most common malignant tumor. Among the 21 benign tumors, 16 cases of pleomorphic adenoma and a case each of myoepithelioma, benign metastasising pleomorphic adenoma, basal cell adenoma, warthins tumor and schwannoma were found. Among the 4 malignant tumors, 2 cases of mucoepidermoid carcinoma, a case of carcinoma ex pleomorphic adenoma and a case of myoepithelial carcinoma were found. Among the 5 non neoplastic lesions a case each of chronic sialadenitis, Sjogren's syndrome, inflammatory myofibroblastic tumor, parotid abscess and lymphoepithelial cyst were found.

Conclusions: The diagnosis of salivary gland lesions by histopathological examination is the most important method in diagnosis and differentiating benign and malignant lesions and to predict prognosis by typing, staging and grading of malignant neoplasms.

Keywords: Salivary gland, Benign tumors, Malignant tumors

INTRODUCTION

Salivary gland neoplasms account for less than 1% of all tumors and 3-5.5% of all head and neck tumors.^{1,2} The worldwide annual incidence of salivary gland tumors ranges from 0.4 to 13.5 cases per 1 lakh. A salivary gland neoplasm consists of a wide variety of benign and malignant tumors. These tumors commonly pose problems

in diagnosis due to their rarity, broad morphological spectrum and morphologic overlap among the different tumor sub-types. These tumors exhibit differences in biological behaviour and also in prognosis.

Parotid gland accounts for nearly 80% of the salivary gland tumors followed by the submandibular gland accounting for approximately 10-15% of the tumors. 80-85% of the

tumors are benign in nature with Pleomorphic adenoma being the most common tumor constituting 70% of benign tumours.³ Mucoepidermoid carcinoma is the most common malignant tumor which involves mostly the parotid gland followed by the minor and submandibular gland.⁴ Although fine needle aspiration cytology (FNAC) is a tool for pre-operative evaluation, histopathology still remains the gold standard in giving the final diagnosis.⁵

Objectives

The present study is undertaken to study age, sex and site distribution of various salivary gland lesions and to study the spectrum of histomorphological features of various salivary gland lesions in correlation with the clinical diagnosis at a tertiary care center.

METHODS

This was an observational, single institutional, both prospective and retrospective study. The materials required for the study were collected from the Department of Pathology, Government. Stanley Medical College, Chennai, Tamil Nadu, India. The surgically resected salivary gland specimens between the period of one year from January 2019 to December 2019 were studied in both retrospective part and in the prospective part. The study was approved by the Institutional Ethics Committee and study procedure was in accordance with the principles of the Declaration of Helsinki.

A total of 30 specimens of salivary gland lesions were analyzed, this study includes both the non-neoplastic and neoplastic lesions of the salivary gland. The specimens consisted of open biopsies, superficial parotidectomies and total parotidectomies with or without resection of the draining lymph nodes.

In the retrospective part of the study history and clinical details were collected from the biopsy register, the blocks and slides were retrieved and studied. In the prospective part of the study patient's history and clinical details were noted from the original request forms, specimens were fixed in formalin and sections were processed and embedded in paraffin after the gross examination. The sections were taken from the lesion, its margins, surrounding tissues and lymph nodes if any. The paraffin blocks were serially cut to get sections of 3-5 µm thickness. These sections were stained with hematoxylin and eosin stains, and in selected cases special stain like PAS was done.

These slides were examined under low power and high power magnification. The details of cellular architecture, encapsulation, perineural and vascular patterns and surrounding areas were studied. The tumors were classified according to World Health Organization's (WHO) histologic typing of salivary gland tumors. Data acquired from examination of each specimen were tabulated using a proforma in a systematic sequence. The

data obtained were then processed using the Statistical package for social sciences (SPSS) software version 20. The processed data were then analyzed and the results obtained were compared with the existing studies in literature.

RESULTS

In this present study 30 specimens of salivary gland lesions were studied. Out of thirty salivary gland specimens examined during our study time period, 25 were neoplastic (83.33%) and 5 were non neoplastic (16.66%).

Table 1: Distribution of salivary gland lesions.

Type of salivary gland lesion	No. of cases
Pleomorphic adenoma	16
Mucoepidermoid carcinoma	2
Myoepithelioma	1
Benign metastasising pleomorphic adenoma	1
Basal cell adenoma	1
Warthins tumor	1
Schwannoma	1
Carcinoma ex pleomorphic adenoma	1
Myoepithelial carcinoma	1
Chronic sialadenitis	1
Sjogren's syndrome	1
Inflammatory myofibroblastic tumor	1
Parotid abscess	1
Lymphoepithelial cyst	1

Table 2: Age group distribution of salivary gland lesions.

Gender	Age group (years)						
	11-20	21-30	31-40	41-50	51-60	61-70	71-80
Male	1	2	4	3	0	3	0
Female	1	3	2	5	2	3	1

Among the 25 neoplastic, 21 were benign (84%) and 5 were malignant (16%). Among the 5 non neoplastic lesions a case each of chronic sialadenitis, Sjogren's syndrome, inflammatory myo-fibroblastic tumor, parotid abscess and lymphoepithelial cyst were found.

Among the 21 benign tumors, 16 cases of pleomorphic adenoma (Figure 1, 2) and a case each of myoepithelioma, benign metastasising pleomorphic adenoma, basal cell adenoma, warthins tumor (Figure 3) and schwannoma were found.

Among the 4 malignant tumors, 2 cases of mucoepidermoid carcinoma (Figure 4, 5), a case of

carcinoma ex pleomorphic adenoma and a case of myoepithelial carcinoma were found (Table 1).

Table 3: Age group distribution of benign salivary neoplasms.

Gender	Age group (years)						
	11-20	21-30	31-40	41-50	51-60	61-70	71-80
Male	1	2	4	3	0	0	0
Female	1	3	2	2	1	1	1

Table 4: Age group distribution of malignant salivary neoplasms.

Gender	Age group (in years)						
	11-20	21-30	31-40	41-50	51-60	61-70	71-80
Male	0	0	0	0	0	1	0
Female	0	0	0	1	0	2	0

Table 5: FNAC and biopsy correlation.

FNAC and Biopsy correlation		
Positive correlation	Negative correlation	Not available
17	6	7

In our study salivary gland lesions showed female preponderance with the peak incidence at 31- 50 years. Among the 30 salivary gland lesions, 17 were found in females in comparison to 13 cases in males (Table 2).

In our present study benign salivary gland neoplasms were seen between 2nd and 8th decade. Of the 21 benign neoplasms majority of these cases were between 21 to 50 years. Male and females were more or less equally affected (10 in males and 11 in females) among the benign neoplasms of salivary gland (Table 3).

In our present study malignant salivary gland neoplasms were commonly seen in 4th and 7th decade. Of the 4 malignant neoplasm majority of the cases were seen in 7th decade. Female preponderance (1 in male and 3 in female) was observed in malignant neoplasms (Table 4).

In our present study salivary gland non neoplastic lesions were seen between 4th and 7th decade. Of the 5 non neoplastic lesions majority of the cases were seen in 5th decade. Female preponderance (1 in males and 4 in females) was observed in non neoplastic lesions.

In our present study of salivary gland lesions FNAC and biopsy showed positive correlation in 17 out of 30 cases, 6 out of 30 cases showed negative correlation, while such correlation were not available in remaining 7 cases (Table 5).

In our present study the salivary gland lesions were more common in parotid gland (n=21), followed by sub-mandibular gland (n=7) and minor salivary gland (n=2). The distributions of salivary gland involvement were depicted. In our present study taking into account the laterality of salivary gland lesions, right side lesions (n=19) were more common compared to left side lesions (n=11). The laterality of salivary gland involvement was depicted.

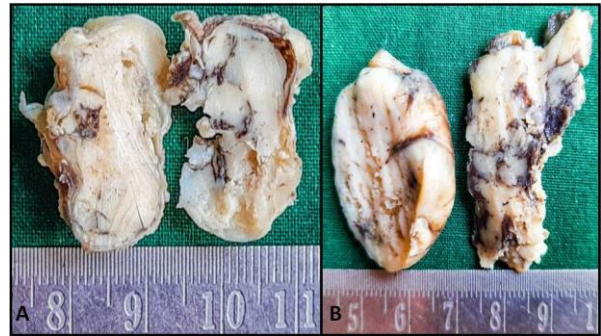


Figure 1: Gross appearance of pleomorphic adenoma of parotid gland. The tumors shown in A and B have a well circumscribed predominantly solid glistening cut surface.

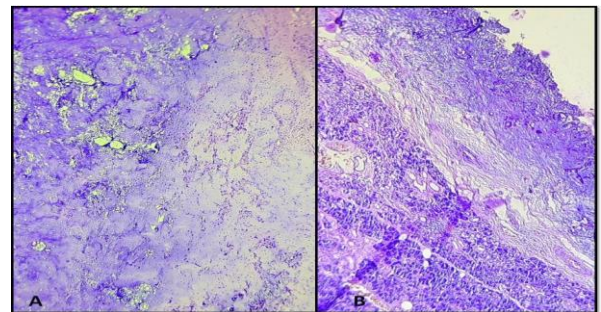


Figure 2: Low power microscopic appearance of Pleomorphic adenoma. A: Myoepithelial cells show cartilaginous metaplasia and they appear to “melt” into the surrounding chondromyxoid stroma. B: Shows normal salivary gland adjacent to the chondromyxoid areas.

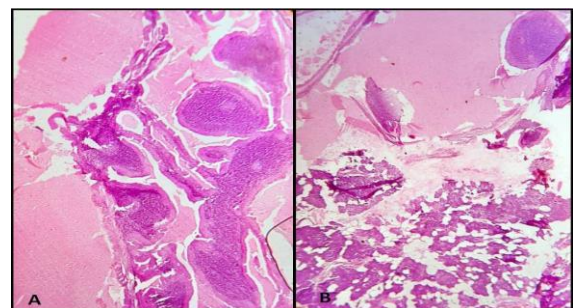


Figure 3: Low-power appearance of Warthin tumor. A: Germinal centers are very prominent with adjoining cystic areas. B: Shows normal salivary gland adjacent to the cystic areas.

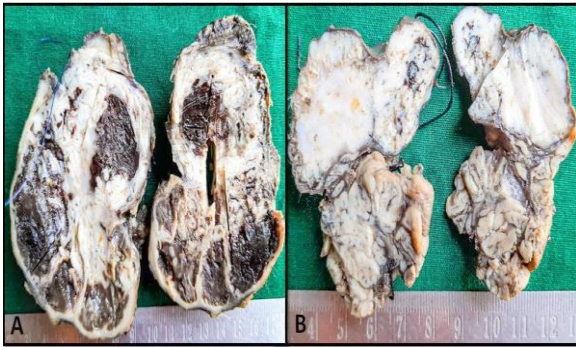


Figure 4: Gross appearance of mucoepidermoid carcinoma A: Showing areas of cyst formation. B: Shows entirely solid tumor, commonly seen in low-grade lesions with an adjoining normal salivary gland.

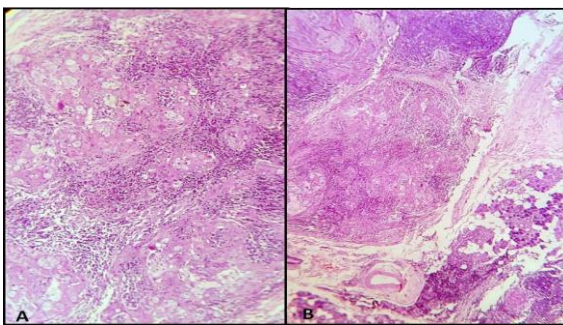


Figure 5: Microscopic appearance of Mucoepidermoid carcinoma. A: Mucous, squamous, and intermediate cells are seen – high power. B: Shows normal salivary gland adjacent to the tumor – low power.

DISCUSSION

Our study revealed that benign tumors were more common than malignant tumors in salivary gland. Pleomorphic adenoma was the most common benign tumor and mucoepidermoid carcinoma was the commonest malignant tumor in our study. Most common age group for salivary gland tumor was between 40-60 years. Parotid gland is the commonest site for various tumors.⁶ Among the various salivary gland lesions, female preponderance was seen in all the categories.

Dandapat et al and Rewsuwan et al reported a female preponderance of salivary gland lesions in their study which was similar to that of our study.^{7,8} Majority of the lesions were benign which predominate over the malignant lesions which was correlating with the studies conducted by Joshi RR et al, Ali et al, Moghadam et al, Vargas et al, Fonseca et al and Venugopal et al.⁹⁻¹⁴

In our present study parotid gland was the commonest site for salivary gland lesions which was similar to studies conducted by Ahmed et al, Vargas et al, Rewsuwan et al and Bashir et al.^{15,12,8,16}

In our study we observed the finding that pleomorphic adenoma was the most common benign tumor, which was similar to the studies conducted by Shrestha et al, Bashir et al and Ali et al.^{17,16,10} We also observed mucoepidermoid carcinoma to be the most common malignant salivary gland tumor similar to the studies of Richardson et al and Ali et al.^{18,10}

In our study benign tumours were seen more often in the lower age group (mean age of 37 years) as compared to the malignant tumours (mean age of 64 years), comparable with the studies of Dave et al. and Soni et al.^{19,20}

In our study age incidence of mucoepidermoid carcinoma was predominantly in 61-70 years age group with female predominance, which correlated well with studies of Laishram et al, Vargas et al and Fonseca et al.^{21,12,13} Parotid gland was the most common site for mucoepidermoid carcinoma followed by submandibular gland, comparable to the studies of Soni et al and Venugopal et al.^{20,14}

In our present study parotid gland was the most commonly affected site (70%) followed by submandibular gland (23%) and minor salivary gland (7%). These findings were in accordance with the studies of Frable and Frable, Cristallini et al and Bocatto et al.²²⁻²⁴ There was a slight female predominance in our present study which was in accordance with the studies of Frable and Frable, Stewart et al and Rajwanshi et al.^{22,25,26}

The p-value for FNAC and histopathological correlation between positive and negative cases for neoplasm was found to be 0.001 which was considered highly significant. Sensitivity, specificity and diagnostic accuracy of FNAC for neoplasms was found to be 74%, 100% and 89% respectively.

CONCLUSION

Most of the salivary gland neoplasms showed overlapping features. Proper diagnosis needs consideration of histological findings to differentiate between benign and malignant neoplasms. From our present study, it was evident that histopathological examination of salivary gland lesions is the most important method in establishing the final diagnosis of malignant neoplasms.

ACKNOWLEDGEMENTS

Authors would like to thank Dr. Nalli R. Sumitra Devi, Dr. Valarmathi K, Dr. Surekha MR, Dr. Sathyalakshmi R and Dr. Subachitra T, Department of Pathology, Govt. Stanley Medical College, Chennai.

Funding: No funding sources

Conflict of interest: None declared

Ethical approval: The study was approved by the Institutional Ethics Committee

REFERENCES

1. Barnes L, Eveson JW, Reichart P. World Health Organization Classification of Tumours: Head and Neck Tumours. IARC Press, Lyon. 2005. Accessed on 09 November, 2020.
2. Cheuk W, John KC. Salivary gland tumors. In: Fletcher C.D.M ed Diagnostic Histopathology of Tumors, 3rd ed. 2007;1.
3. Arey LB. Developmental Anatomy. WB Saunders, Philadelphia. 1974.
4. Dardick I, Thomas MJ, Van Nostrand AW. Myoepithelioma new concepts of histology and classification: A light and electron microscopic study. *Ultrastruct Pathol.* 1989;13:187-224.
5. Denny PC, Ball WD, Redman RS. Salivary glands: A paradigm for diversity of gland development. *Crit Rev Oral Biol Med.* 1997;8:51-75.
6. Kumar AA, Rakshitha HB, Alva NK, Reginald SR. Histopathological spectrum of salivary gland neoplasms in a tertiary care center. 2019;2(1):243-46.
7. Dandapat MC, Rath BK, Patnaik BK, Dash SN. Tumors of salivary glands. *Indian J Surg.* 1991;53:200.
8. Rewsuwan S, Settakorn J, Mahanupab P. Salivary gland tumors in Maharaj Nakorn Chiang Mai Hospital: a retrospective study of 198 cases. *Chiang Mai Med Bull.* 2006;45(2):45-3.
9. Joshi RR, Nepal A, Chettri ST, Bhattarai M, Ghimire A, Karki S. Primary salivary gland tumors in eastern Nepal tertiary care hospital. *Journal of Nepal Health Research Council.* 2010;8(1).
10. Ali NS, Nawaz A, Rajput S, Ikram M. Parotidectomy: a review of 112 patients treated at a teaching hospital in Pakistan. *Asian Pacific journal of cancer prevention.* APJCP. 2010;11(4):1111.
11. Moghadam SA, Moghadam FA, Dadfar M. Epithelial salivary gland tumors in Ahvaz, Southwest of Iran. *Journal of dental research, dental clinics, dental prospects.* 2010;4(4):120.
12. Vargas PA, Gerhard R, Araújo Filho VJ, Castro IV. Salivary gland tumors in a Brazilian population: a retrospective study of 124 cases. *Revista do Hospital das Clinicas.* 2002;57(6):271-6.
13. Fonseca FP, de Vasconcelos Carvalho M, de Almeida OP, Rangel AL, Takizawa MC, Bueno AG, Vargas PA. Clinicopathologic analysis of 493 cases of salivary gland tumors in a Southern Brazilian population. *Oral surgery, oral medicine, oral pathology and oral radiology.* 2012;114(2):230-9.
14. Venugopal M, Devi CP, Deepthi K, Mutte K. The dynamics of diagnosis of salivary gland tumours: histopathology matters. *International Journal of Research in Medical Sciences.* 2016;4(6):1855.
15. Ahnrad S, Lateef M, Ahmad R. Clinicopathological study of primary salivary-gland tumors in Kashmir. *JK-practitioner.* 2002;9(4):231-3.
16. Bashir S, Mustafa F, Malla HA, Khan AH, Rasool M, Sharma S. Histopathological spectrum of salivary gland tumors: A 10 year experience. *Sch J App Med Sci.* 2013;1(6):1070-4.
17. Shrestha S, Pandey GK, Pun CB, Bhatta R, Shahi R. Histopathological pattern of salivary gland tumors. *Journal of Pathology of Nepal.* 2014;4(7):520-4.
18. Richardson GS, Dickason WL, Gaisford JC, Hanna DC. Tumors of salivary glands: An analysis of 752 cases. *Plastic and Reconstructive Surgery.* 1975;55(2):131-8.
19. Dave PN, Parikh UR, Goswami HM, Jobanputra GP, Panchal NV, Shah AM. Histopathological study of salivary gland lesions. *International Journal of Current Research and Review.* 2015;7(17):45.
20. Soni D, Mathur K, Yadav A, Kumar V. Histopathological spectrum of salivary gland lesions in tertiary care center at SMS Medical College Jaipur Rajasthan. *Int J Med Res Pro.* 2016;2:209-15.
21. Laishram RS, Kumar KA, Pukhrambam GD, Laishram S, Debnath K. Pattern of salivary gland tumors in Manipur, India: A 10 year study. *South Asian journal of cancer.* 2013;2(4):250.
22. Frable MA, Frable WJ. Fine-needle aspiration biopsy of salivary glands. *The Laryngoscope.* 1991;101(3):245-9.
23. Cristallini EG, Ascani S, Farabi R, Liberati F, Macciò T, Peciarolo A, Bolis GB. Fine needle aspiration biopsy of salivary gland, 1985-1995. *Acta cytologica.* 1997;41(5):1421-5.
24. Boccato P, Altavilla G, Blandamura S. Fine needle aspiration biopsy of salivary gland lesions. A reappraisal of pitfalls and problems. *Acta cytologica.* 1998;42(4):888-98.
25. Stewart CJ, MacKenzie K, McGarry GW, Mowat A. Fine-needle aspiration cytology of salivary gland: a review of 341 cases. *Diagnostic cytopathology.* 2000;22(3):139-46.
26. Rajwanshi A, Gupta K, Gupta N, Shukla R, Srinivasan R, Nijhawan R, Vasishta R. Fine-needle aspiration cytology of salivary glands: diagnostic pitfalls—revisited. *Diagnostic cytopathology.* 2006;34(8):580-4.

Cite this article as: Srinivasan G, Joseph FAJ, Kaliyaperumal S, Ponnaiah A. Histopathological spectrum of salivary gland lesions - in a tertiary care centre. *Int J Res Med Sci* 2021;9:97-101.