

Original Research Article

Pathologies associated with impacted maxillary canine tooth in patients presenting at a tertiary care hospital

Usman Qadir Khan^{1*}, Abid Raza², Qaimuddin Shaikh³, Saadia Nazir⁴, Nadia Ambreen⁴

¹Department of Oral and Maxillofacial Surgery, Shahida Islam Medical and Dental College, Lodhran, Pakistan

²Department of Oral and Maxillofacial Surgery, King Khaled Hospital, Tabuk, Saudi Arabia

³Department of Oral and Maxillofacial Surgery, Bibi Aseefa Dental College, Shaheed Mohtarama Benazir Bhutto University, Larkana, Pakistan

⁴Dental and Oral surgery Department, Shaikh Zayed Medical College and Hospital, Rahim Yar Khan, Pakistan

Received: 01 December 2020

Accepted: 17 December 2020

*Correspondence:

Dr. Usman Qadir Khan,

E-mail: drkhan381@gmail.com

Copyright: © the author(s), publisher and licensee Medip Academy. This is an open-access article distributed under the terms of the Creative Commons Attribution Non-Commercial License, which permits unrestricted non-commercial use, distribution, and reproduction in any medium, provided the original work is properly cited.

ABSTRACT

Background: The pathologies associated with impacted maxillary canine tooth presented as radiolucent, radiopaque and mixed radiolucent radiopaque lesions on radiographs and adenomatoid odontogenic tumor was the most common pathology associated with it followed by dentigerous cyst, odontoma and calcifying odontogenic cyst after histopathological confirmation. This study was planned to determine the frequency of pathologies associated with impacted maxillary canine tooth in patients presenting at a tertiary care hospital.

Methods: This cross-sectional survey was conducted at Dental / Oral Surgery Department, Shaikh Zayed Medical College / Hospital, Rahim Yar Khan, Pakistan from January to December 2017. A total of 60 patients with clinical and radiographic diagnosis of impacted maxillary canine tooth were enrolled. Orthopantomogram and/or para nasal sinus view were considered as the standard radiograph for assessment of pathologies associated with impacted maxillary canine tooth which were confirmed by histopathological examination. Demographics and radiographic findings and histopathological confirmation of pathologies were noted.

Results: Out of a total of 60 patients, 38 (63.33%) pathologies associated with impacted maxillary canine presented as radiolucent lesion, 11 (18.33%) each presented as radiopaque and mixed radiolucent radiopaque lesion. Adenomatoid odontogenic tumor (30%) was the most common pathology associated with impacted maxillary canine tooth. The other pathologies associated were dentigerous cyst (26.67%), odontoma (18.33%), calcifying odontogenic cyst (11.66%), calcifying odontogenic cyst with an odontoma (6.66%), Odontogenic keratocyst (3.33%) and Ameloblastoma (3.33%).

Conclusions: The most common pathology occurring predominantly with impacted maxillary canine tooth was adenomatoid odontogenic tumor followed by dentigerous cyst, odontoma and calcifying odontogenic cyst.

Keywords: Impacted tooth, Canine, Adenomatoid odontogenic tumor, Dentigerous cyst

INTRODUCTION

An impacted tooth is a partial or complete unerupted tooth due to an obstruction or lack of space to erupt.¹ The term impaction was defined by Peterson as one that fails to erupt into the dental arch within the expected time.²

These impactions are probably the result of lack of space, genetic, environmental factors, infections, pathological conditions such as tumor or cyst.^{3,4} The teeth most commonly impacted are mandibular and maxillary third molars, followed by maxillary canine and mandibular premolar.² The incidence of impacted maxillary canine has been reported to vary between 0.8 to 2.8%.^{5,6}

However, one study shows the prevalence of canine impaction to be 28.1%.⁷

The impacted teeth are known to be associated with the risk of development of different complications and pathologies like carries, pulp disease, periapical and periodontal disease, infection of facial space, root resorption of adjacent tooth and even oral and maxillofacial cyst and tumor.⁷ The most common pathologies associated with impacted maxillary canine tooth are cysts (dentigerous cyst, calcifying odontogenic cyst) or tumors (adenomatoid odontogenic tumor, odontoma).⁸⁻¹⁰ Impacted canines are the most common teeth associated with adenomatoid odontogenic tumor and their incidence in maxilla is 51.3%.⁸ The incidence of dentigerous cyst in maxilla with impacted canine is 30%.¹¹ The clinical presentation of these pathologies is usually similar that are discovered on routine radiographs. Radiographically they present either as radiolucent or radiopaque lesions or mixed radiolucent-radiopaque lesions. Histopathological examination is the only way of differentiating these pathologies.¹² These pathologies cause ectopic eruption and displacement of impacted canine tooth into the adjacent structure like maxillary sinus. The sequelae of these pathologies vary from obstruction of sinus to blindness.¹¹ Also, some untreated dentigerous cysts have potential to develop odontogenic tumors like ameloblastoma and malignancies like oral squamous cell carcinoma and mucoepidermoid carcinoma.¹³

The rationale of our study was to determine the frequency of pathologies associated with impacted maxillary canine tooth so that we can make guideline for the assessment of patients before the development of pathologies to reduce morbidity due to pathologies associated with impacted maxillary canine tooth, and to reduce cost associated with surgical intervention done for eradication of the pathology. Most of the literature available on this topic is international but very little work has been done locally. This study will provide magnitudes of pathologies related to impacted maxillary canine tooth in our local population.

METHODS

This cross-sectional survey was conducted at Dental/Oral Surgery Department, Shaikh Zayed Medical College/Hospital, Rahim Yar Khan, Pakistan from January to December 2017. A sample size of 60 cases was calculated with 95% confidence interval, 12% margin of error and taking expected percentage of dentigerous cyst that is 30%. 11 in patients presenting with impacted maxillary canine tooth.

Inclusion criteria

Patients of both genders and all age groups, presented with facial swelling in the absence of maxillary canine tooth, assessed clinically and radiographically.

Exclusion criteria

Patients having pathologies developing around impacted supernumerary teeth (an extra tooth which is assessed radiographically in addition to normal 32 teeth).

An informed consent was obtained from patients after explaining study protocol, use of data for research and risk/benefits. Patient's demographic data like age and gender were collected on a specially designed proforma. Radiographical {(orthopantomogram (OPG) and/or para nasal sinus (PNS)} and histopathological examination were recorded on proforma. The radiographic examination was radiolucency or radiopacity or mixed radiolucent-radiopaque lesion associated with impacted maxillary canine tooth. Biopsy was performed by a single operator to remove the bias.

Histopathological confirmation of the associated pathology was done from a single laboratory. Impacted tooth was defined as the one which fails to erupt into dental arch within expected time which was assessed clinically by doing intra oral examination and radiographically by orthopantomogram (OPG) and /or para nasal sinus view (PNS). In terms of pathologies, dentigerous cyst was labelled as a cyst surrounding the crown of an unerupted tooth and is dilatation of the follicle presenting radiographically as well circumscribed round unilocular radiolucency and was confirmed histopathologically by performing incisional biopsy. Calcifying odontogenic cyst was described as a cyst predominantly an intraosseous may be extraosseous presenting radiographically as well circumscribed unilocular or multilocular radiolucency with some areas of radiopacity and confirmed histopathologically by performing incisional biopsy. Adenomatoid odontogenic tumor was labelled as a tumor surrounding the crown of an unerupted tooth radiographically presenting as well circumscribed unilocular radiolucency and confirmed histopathologically by performing incisional biopsy. Odontoma was labelled as an odontogenic tumor taking as hamartomas rather than true neoplasm presenting radiographically as multiple small radiopaque teeth like masses (compound odontoma) or radiopaque cauliflower like mass (complex odontoma) and confirmed histopathologically by performing incisional biopsy.

Data collected was entered on SPSS version 26.0. The qualitative variables in data like gender and outcome variables (dentigerous cyst, calcifying odontogenic cyst, adenomatoid odontogenic tumor, odontoma and others) were presented as frequency and percentages. The quantitative data that is age were presented as mean with standard deviation.

RESULTS

Out of a total of 60 patients, 31 (51.67%) were female. The mean age of the patients was 22.52 years (SD ± 11.512 years) with an age range of 6 to 46 years. The

mean age of males was 21.90 years (SD±10.448 years) while the mean age of females was 22.0 years (SD±10.123 years).

Figure 1 is showing distribution of patients according to radiographic features associated with impacted maxillary canine tooth. Radiolucent was the most common radiographic feature noted.

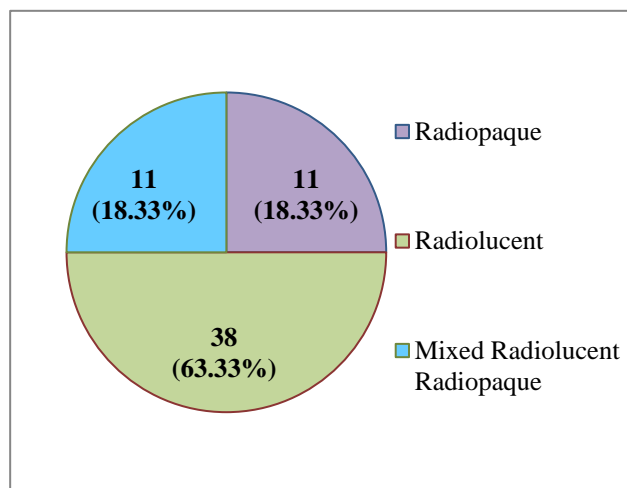


Figure 1: Distribution of patients according to radiographic features associated with impacted maxillary canine tooth.

Adenomatoid odontogenic tumor followed by dentigerous cyst and odontoma were found to be the most common histopathological finding noted in 18 (30.0%), 16 (26.67%) and 11 (18.33%) respectively. Figure 2 is showing various pathological findings noted among the study subjects.

It was seen that age between 11 to 20 years was the commonest among our patients, noted among 26 (43.33%) cases. Table 1 is showing distribution of pathological findings according to age and gender.

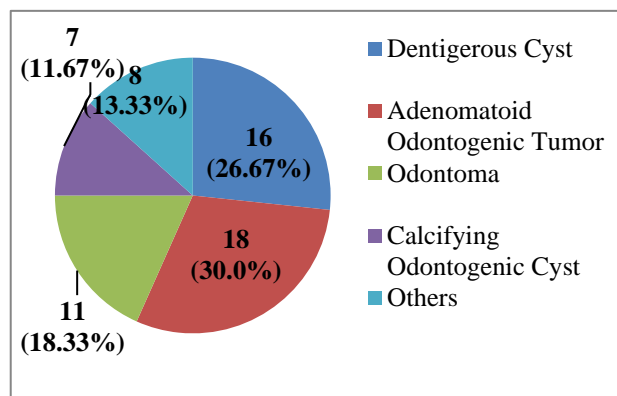


Figure 2: Distribution of patients according to histopathological examination of pathologies associated with impacted maxillary canine tooth.

Table 1: Pathological distribution according to age and gender among patients with impacted maxillary canine tooth.

Pathological distribution	Gender	Age (years) distribution				
		0-10	11-20	21-30	31-40	40+
Dentigerous cyst	Male	1	4	2	1	1
	Female	1	3	2	1	0
Adenomatoid odontogenic tumor	Male	0	4	1	0	1
	Female	1	5	4	2	0
Odontoma	Male	1	3	1	0	1
	Female	1	2	0	1	1
Calcifying odontogenic cyst	Male	0	2	2	0	0
	Female	0	1	0	1	1
Others	Male	1	1	1	1	0
	Female	0	1	1	1	1

DISCUSSION

Impacted teeth are known to be associated with the development of different complications and pathologies like caries, periapical and periodontal disease, pulp disease, infection of facial space and oral and maxillofacial cyst and tumor.⁷ The mean age of patients in this study was 21.95 years (SD±10.194) with an age range of 6 to 46 years. The mean ages of males and females were not also different (21.90 years (SD±10.448) and 22.00 years (SD±10.123)). There can be two reasons for the presentation in the young age range. First, the

eruption time of canine which would be 11 to 13 years i.e. if the canine is not erupted until its expected time it means it becomes impacted with its follicle developing pathology around it. Secondly, due to poor socio-economic status and lack of routine dental check-up, the patients present mostly when they become symptomatic like swelling and pathology is developed. This shows that patients with young age group have more chances of developing pathologies with impacted maxillary canine tooth. Most studies with pathologies associated with impacted maxillary canines also showed the same incidence.^{14,15}

In the present study, 63.33% patients were initially diagnosed on radiographs as having radiolucent lesions while 18.33% each were having radiopaque and mixed radiolucent radiopaque lesions. Orthopantomogram (OPG) and/or paranasal sinus view (PNS) were used since these are simple and inexpensive methods that can be used in daily practice. The structure of a tooth with associated pathology can be clearly detected on panoramic radiographs and PNS view gives picture of maxillary sinus if an impacted tooth is displaced into it. It was difficult to establish a definitive diagnosis on the basis of radiographic features. However, Freedland and Henneman¹⁶ reported that when a mass is identified within the maxillary sinus, CT scan is preferred to determine the exact position of lesion. CT scans provide superior bony detail allowing for the visualization of the size and extent of lesion with determination of orbital or nasal invasion or involvement. We cannot deny the importance of CT scan for its imaging features over normal radiographs but dilemma is that our local population belongs to poor socio-economic class and our government doesn't provide facility of CT scan at free of cost as our population cannot afford such expensive radiograph. Pathologies that presented with radiolucent lesion in anterior maxilla with impacted canine on radiographs were adenomatoid odontogenic tumor (AOT 47.3%), dentigerous cyst (42.1%), Ameloblastoma (5.3%), odontogenic keratocyst (5.3%) out of 38 radiolucent lesions in total 60 patients sample which were confirmed on histopathological examination. Odontoma [100% (compound or complex)], calcifying odontogenic cyst (63.63%) and calcifying odontogenic cyst with an odontoma (36.37%) were the pathologies that presented with radiopaque and mixed radiolucent radiopaque lesion on radiographs out of 11 radiopaque and 11 mixed radiolucent radiopaque lesions respectively in total 60 patient's sample which were confirmed on histopathological examination. Most of the literature reveals that since patients presenting with these pathologies are asymptomatic so they are mostly disclosed on routine radiographs.^{12,17} This is a blessing situation in western countries where people have awareness and routine dental checkup and government provides health care facilities. On the contrary, situation in Pakistan is not so good because people are not educated and most of our population lives in rural areas. They do not have licensed practitioners in their local setup for proper diagnosis so they usually present late to tertiary care hospitals when they become symptomatic with pathology.

The most common pathology that was diagnosed histopathologically associated with impacted maxillary canine was adenomatoid odontogenic tumor (AOT). Most studies support this assertion that impacted canines are associated with AOT.¹⁸⁻²⁰ Swadison et al¹⁸ in 67 cases in Thai population found that canines were the most common teeth associated with AOT and maxillary canines accounted for 51.3% of all cases. Arotiba et al in an analysis of 57 cases of black African population found

that this incidence was even higher to 61.5%.¹⁸ The reason for this high incidence could be that they studied the association of AOT with any impacted or embedded teeth.

The limitations of this study were that the sample size of patients was small. Also, clinical presentation of swellings associated with pathologies like asymptomatic (painless) or symptomatic features (pain, infection, nasal blockade, nasal bleeding and exudates) were not recorded. The duration of symptoms associated with pathologies were also not recorded. Findings on radiographs like unilocularity or multilocularity of lesions, displacement of teeth and root resorption associated with pathologies were not recorded. This study was conducted at single institute which helped in determining the frequency of pathologies in local population but not the incidence or prevalence of whole population at gross level.

CONCLUSION

Adenomatoid odontogenic tumor was the most common pathology associated with impacted maxillary canine tooth. The other pathologies in decreasing order were dentigerous cyst, odontoma, calcifying odontogenic cyst, COC with an odontoma, OKC and ameloblastoma. Most of these pathologies are asymptomatic and are discovered on routine radiographs. Young persons are more prone to these pathologies as compared to old persons.

ACKNOWLEDGEMENTS

The authors of this research are thankful to Mr. Muhammad Aamir (Research Consultant, Bahawalpur) for his volunteer support in statistical analysis.

Funding: No funding sources

Conflict of interest: None declared

Ethical approval: The study was approved by the Institutional Ethics Committee

REFERENCES

1. Passi D, Singh G, Dutta S, Srivastava D, Chandra L, Mishra S, et al. Study of pattern and prevalence of mandibular impacted third molar among Delhi-National Capital Region population with newer proposed classification of mandibular impacted third molar: A retrospective study. *Natl J Maxillofac Surg.* 2019;10(1):59-67.
2. Peterson LJ. Principles of Management of Impacted Teeth. In: Peterson LJ, Ellis III E, Hupp JR, Tucker MR, (Eds). *Contemporary Oral & Maxillo-Facial Surgery.* 3rd ed. St. Louis: Mosby 1998:215-48.
3. Kaczor-Urbanowicz K, Zadurska M, Czochrowska E. Impacted teeth: An interdisciplinary perspective. *Adv Clin Exp Med.* 2016;25(3):575-85.
4. Al-Abdallah M, AlHadidi A, Hammad M, Dar-Odeh N. What factors affect the severity of

- permanent tooth impaction? *Bio Med Cent Oral Health.* 2018;18(1):184.
5. Shah RM, Boyd MA, Vakll TF. Studies of permanent tooth anomalies in 7886 Canadian individuals. *J Can Dent Assoc.* 1978;44:262-4.
 6. Grover PS, Lorton L. The incidence of unerupted permanent teeth and related clinical cases. *Oral Surg Oral Med Oral Pathol.* 1985;59:420-9.
 7. Hou R, Kong L, Ao L, Liu G, Zhou H, Qin R, et al. Investigation of impacted permanent teeth except the third molar in Chinese patients through an x-ray study. *J Oral Maxillofac Surg.* 2010;68:762-7.
 8. Swadison S, Dhanuthai K, Jainkittivong A, Philipsen HP, Odont. Adenomatoid odontogenic tumor: An analysis of 67 cases in Thai population. *Oral Surg Oral Med Oral Pathol Oral Radiol Endod.* 2008;105:210-5.
 9. Rajkumar K, Kamal K, Satish MR, Leena S. Calcifying Odontogenic Cyst. *J Oral Maxillofac Pathol.* 2004;8:99-103.
 10. Philipsen HP, Reichart PA, Praetorius F. Mixed odontogenic tumors and Odontomas: Considerations on interrelationship. Review of the literature and presentation of 134 new cases of odontomas. *Oral Oncol.* 1997;33(2):86-99.
 11. Buyukkurt MC, Omezli MM O. Dentigerous cyst associated with an ectopic tooth in maxillary sinus: a report of 3 cases and review of the literature. *Oral Surg Oral med Oral Pathol Oral Radiolo Oral Endod.* 2010;109:67-71.
 12. Neville BW, Damm DD, Allen CM, Bouquot JE. Odontogenic cysts and tumors. In: *Oral and maxillofacial Pathology.* 2nd ed. Philadelphia: WB Saunders; 2002:589-642.
 13. Slootweg PJ. Carcinoma arising from reduced enamel epithelium. *J Oral Pathol.* 1987;16:479-82.
 14. Sarica I, Derindag G, Kurtuldu E, Naralan ME, Caglayan F. A retrospective study: Do all impacted teeth cause pathology? *Niger J Clin Pract.* 2019;22(4):527-33.
 15. Mohammed M, Mahomed F, Ngwenya S. A survey of pathology specimens associated with impacted teeth over a 21-year period. *Med Oral Patol Oral Cir Bucal.* 2019;24(5):e571-6.
 16. Freedland ES, Henneman PL. An unusual cause of headache: a dentigerous cyst in the maxillary sinus. *Ann Emerg Med.* 1987;16:1174-6.
 17. Buchner A. The central (intraosseous) calcifying odontogenic cyst: an analysis of 215 cases. *J Oral Maxillofac Surg.* 1991;49(4):330-9.
 18. Arotiba GT, Arotiba JT, Olaitan AA, Ajayi OF. The adenomatoid odontogenic tumor: an analysis of 57 cases in a BlackAfrican population. *J Oral Maxillofac Surg.* 1997;55:146-8.
 19. Mendis BR, Macdonald DG. Adenomatoid Odontogenic tumor : A survey of 21 cases from sri lanka .*Int J Oral Maxillofac Surg.* 1990;19:141-3.
 20. Mohamed A, Singh AS, Raubenheimer EJ, Bouckaert MMR. Adenomatoid odontogenic tumour: review of the literature and an analysis of 33 cases from South Africa. *Int J Oral Maxillofac Surg.* 2010;39:843-6.

Cite this article as: Khan UQ, Raza A, Shaikh Q, Nazir S, Ambreen N. Pathologies associated with impacted maxillary canine tooth in patients presenting at a tertiary care hospital. *Int J Res Med Sci* 2021;9:34-8.