

Case Report

Guillain-Barré syndrome: a rare association of COVID-19 pneumonia at presentation

Hemant Mahur, Kartikeya Mathur*, D. P. Singh, Umesh Chahar,
Darshan R. S., Shivakanth M. S.

Department of Medicine, RNT Medical College, Udaipur, Rajasthan, India

Received: 23 January 2021

Revised: 06 March 2021

Accepted: 08 March 2021

*Correspondence:

Dr. Kartikeya Mathur,

E-mail: kartikeyamathur1@gmail.com

Copyright: © the author(s), publisher and licensee Medip Academy. This is an open-access article distributed under the terms of the Creative Commons Attribution Non-Commercial License, which permits unrestricted non-commercial use, distribution, and reproduction in any medium, provided the original work is properly cited.

ABSTRACT

COVID-19 is a global pandemic which has varied array of symptoms. A neurotropic presentation has also been described of which the most common is stroke. In this brief communication we report a case of COVID-19 who presented to our hospital with features suggestive of Guillain-Barré syndrome. A 76 year old male presented with chief complains of weakness in both lower limbs. On detailed examination the patient had LMN type quadriparesis without sensory involvement. Diagnosis of GBS was confirmed by CSF and NCV studies and other cases of quadriparesis were ruled out by appropriate investigations and treatment of the same was started. Respiratory examination revealed bilateral basal crepitations and CXR revealed B/L lower zone haziness so a secondary diagnosis of B/L Atypical Pneumonitis suspected COVID-19 was kept. A COVID-19 RTPCR turned out to be negative initially. However, looking at respiratory signs and symptoms along with increase in inflammatory markers a repeat COVID RTPCR was planned which turned out to be positive. Patient was further managed on the line of COVID-19 pneumonitis. He responded well to the treatment and is now asymptomatic on follow up. Nervous system involvement in COVID-19 may have been grossly underestimated. Over the course of this pandemic, an increasing number of COVID-19 patients are being reported with neurological complications. Physicians should be aware of atypical presentation where patient complained of weakness first and had respiratory symptoms later as in our case where early detection of atypical presentations help in better management.

Keywords: Guillain-Barré syndrome, COVID-19, Pneumonia

INTRODUCTION

Globally, more than 12 million people have been infected with SARS CoV-2 till date with more than 500,000 fatalities.¹ Although, evolution in COVID-19 research is taking place rapidly, new findings need to be thoroughly checked before any conclusion or treatment protocol is formed.² Although, COVID-19 commonly presents with marked respiratory symptoms within the sort of cough and dyspnoea, a

neurotropic presentation has been described lately also.³ Guillain-Barre syndrome (GBS) is best described as an acute inflammatory polyradiculoneuropathy clinically characterised by areflexia and progressive weakness of arms and legs. Though, many rare variants of GBS are described, the commonly observed subtypes like acute motor axonal neuropathy (AMAN), acute motor sensory axonal neuropathy (AMSAN) and acute inflammatory demyelinating polyradiculoneuropathy (AIDP) tend to

fulfil the above-mentioned criteria.⁴ In this brief communication we report a case of COVID-19 who presented to our hospital with features suggestive of GBS.

CASE REPORT

A 76 year old male presented to our medicine OPD with chief complains of weakness in both lower limbs since 5 days. Patient was subsequently admitted in general medicine ward for further evaluation. Patient's weakness was insidious in onset and gradually progressive in nature. Patient had no history of fever, no history of loose stools, vomiting and no history of cough and shortness of breath. There was no history of chronic illness like Type-2 diabetes, hypertension, tuberculosis, bronchial asthma, COPD, HIV, epilepsy, etc. Patient was non-smoker and non-alcoholic. General physical examination revealed no significant abnormalities. Patient's vitals at the time of admission were PR-110/min (regular), BP-140/80 mmHg, RR-22/min, temperature-afebrile and Spo2-98% at room air.

On systemic examination, CNS examination revealed generalised reduction in power in all four limbs (power in left and right lower limbs, 4/5 and power in both upper limbs 4+/5), generalised areflexia. Rest of the CNS examination was normal. Respiratory examination revealed bilateral basal crepitations (R>L). While per abdomen and cardiovascular examination revealed no significant abnormality. A Primary Diagnosis of Guillain Barre syndrome (GBS) with a secondary diagnosis of B/L atypical pneumonitis suspected COVID-19 was made. Investigation to rule out other causes of quadriparesis was done. Serum electrolytes and Serum creatinine kinase turned out to be within normal range and HIV-non reactive. Patient was planned lumbar puncture for CSF analysis and NCV studies to confirm diagnosis of GBS. CSF analysis revealed elevated protein with paucity of cells (protein -83.80 mg/dl and total cell count of 2 cells/cumm), ADA was normal (7.5 U/l) and CSF culture being sterile.

NCV studies was conducted in both upper and lower limbs (tibial, peroneal, sural, median and ulnar nerves). Findings were; peroneal normal distal latency, reduced CMAP amplitude and NCV. Tibial nerve study showed prolonged latency, reduced amplitude and NCV. F-wave non recordable in all tested nerves. Sural nerve conduction study revealed reduced SNAP amplitude while normal parameters in other tested nerves. Other nerves tested normal for these parameters. These findings were suggestive of sensory motor axonal type polyradiculopathy. As per clinical findings CSF study and NCV studies, the primary diagnosis of GBS was confirmed and patient was started on IVIG at a dose of 400 mg/Kg/day for 5 days. Meanwhile patient's CXR revealed B/L lower zone haziness (R>L) as seen in (Figure 1).

So, a COVID-19 RTPCR was sent but it turned out to be negative on day 2. However, by the end of day 3 patient's SpO2 started falling to 84% at room air, ABG analysis revealed type 1 respiratory failure with mild ARDS. Patient was shifted to intensive care unit and was taken on O₂ support via face mask on 10L/min and IVIG was continued with IV antibiotics and other supportive treatment. Patient's blood pressure started fluctuating. Patient developed arrhythmia in form of atrial tachycardia with variable block, for which amiodarone injection was given for 2 days and diltiazem injection, IV bolus followed by tablet diltiazem 30 mg PO TDS was given. After 3 days the rate came under control and a diagnosis of autonomic dysfunction secondary to GBS was made. A repeat CXR PA was planned and inflammatory markers sent.

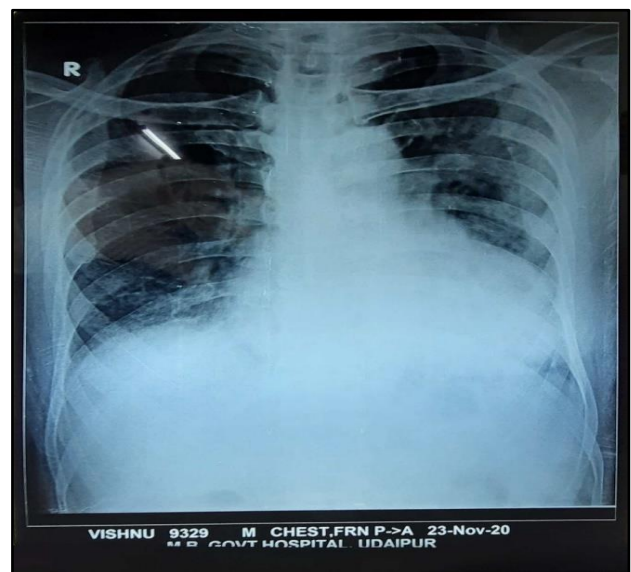


Figure 1: CXR PA view showing B/L lower zone haziness R>L.

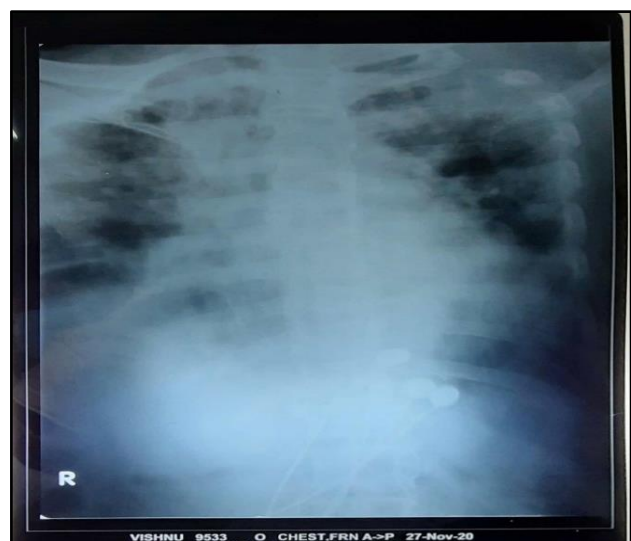


Figure 2: B/L extensive infiltrates involving all zones

Repeat CXR revealed B/L extensive infiltrates as shown in (Figure 2). Inflammatory markers were raised many folds above normal values (IL-6-532.3 pg/ml, ferritin-790 ng/ml, CRP-170 mg/ml). All these findings made possibility of COVID-19 pneumonitis more likely even after first RTPCR being negative, so a repeat COVID-19 RTPCR was done and this time the test turned out to be positive and patient shifted to dedicated COVID-19 hospital. Meanwhile patient's IVIG dose got completed (120 g given for 5 days), and there was improvement in patients power by then.

Patient was further managed on the line of severe COVID-19 pneumonitis and he responded well to the treatment and was subsequently discharged after 12 days and he is now reported to be asymptomatic on follow up.

DISCUSSION

A member of the beta-coronaviridae family, SARS-CoV-2 is a non-segmented, enveloped, single-stranded, positive-sense RNA virus. The mechanisms by which COVID-19 causes neurologic damage are multifactorial, that includes direct damage to specific receptors, cytokine-mediated injury, secondary hypoxia, and retrograde travel along nerve fibres.⁵ In the past GBS has been related to variety of viral infections, last to Zika virus.⁶ The pathogenesis of GBS secondary to COVID-19 isn't clear. It is well documented that the cross immunity which plays a crucial role in GBS secondary to bacterial infections such as *C. Jejuni* may not be the main reason behind GBS associated with other viral infections such as dengue and zika. It is hypothesised that viral illnesses related GBS could be due to autoantibodies or direct neurotoxic effects of viruses.⁷ As the patient had positive RTPCR, throat swab test and CSF examination did not show any raised cell count, thus favouring immune mediated hypothesis. This was further strengthened by a superb response to IVIG, thus favouring an immune mediated pathogenesis instead of direct viral damage.

The patient did not have cranial nerve involvement. This was in contrast to typical GBS, wherein nerve involvement is sort of common. Less frequent involvement of cranial nerves in GBS secondary to SARS-COV-2 is also in contrast to Zika virus associated GBS, where facial and oculomotor nerve involvement was quite common.⁷ The patient had significantly raised pro-inflammatory markers that might suggest a causal link to pro-inflammatory state secondary to COVID-19. Similar rise in inflammatory markers were noted in other case reports also, and it had been hypothesised that these inflammatory mediators and cytokines may play a task in triggering an immune mediated neuropathy.⁸

The patient developed features of GBS first and then had respiratory symptoms which was in contrast to several case reports where Guillain-Barré syndrome resulted 5–10 days after the onset of COVID-19 symptoms.⁹ Patient had an excellent response to IVIG and were ambulatory

without support within 10 days of starting treatment. Previous case reports show mixed treatment response with some reporting excellent recovery, while others reported minimal or delayed response.^{9,10}

CONCLUSION

Nervous system involvement in COVID-19 is grossly underestimated. Over the course of this pandemic, a number of COVID-19 patients are being reported with neurological complications. Some of these neurological presentations, especially GBS has quite effective treatment options. In this era of pandemic, it's important for the physicians to remember the association of GBS with COVID-19, as early diagnosis and treatment of this complication could have gratifying results. Physicians should also be aware of atypical presentation where patient complained of weakness first and had respiratory symptoms later, so a strong index of suspicion should be there, like in our case. It is also important to differentiate GBS from other illness like critical illness neuropathy and respiratory distress secondary to COVID-19 itself, as treatment to the above conditions is sort of different and inability to correctly diagnose could lead to significant increase in morbidity and mortality.

Funding: No funding sources

Conflict of interest: None declared

Ethical approval: Not required

REFERENCES

- Hinson KF, Moon AJ, Plummer NS. World health organization, coronavirus disease (COVID-19): situation report. Available at: <https://www.who.int/emergencies/diseases/novel-coronavirus-2019/situation-reports>. Accessed on 20 December 2020.
- Carrillo-Larco RM, Altez-Fernandez C, Ravaglia S, Vizcarra JA. COVID-19 and Guillain-Barre Syndrome: A systematic review of case reports. *Wellcome Open Res.* 2020;5:107.
- Mao L, Jin H, Wang M. Neurologic manifestations of hospitalized patients with coronavirus disease 2019 in Wuhan, China. *JAMA Neurol.* 2020;77:1-9.
- Piccione EA, Salame K, Katirji B. Guillain-Barré syndrome and related disorders in neuromuscular disorders in clinical practice. New York: Springer; 2014:573-603.
- Bridwell R, Long B, Gottlieb M. Neurologic complications of COVID-19. *Am J Emerg Med.* 2020;38:1549.e3-7.
- Virani A, Rabold E, Hanson T. Guillain-Barré syndrome associated with SARS-CoV-2 infection. *ID Cases.* 2020;20e00771.
- Gupta A, Paliwal VK, Garg RK. Is COVID-19-related Guillain-Barré syndrome different? *Brain Behav Immun.* 2020;87:177-8.
- Benvenuto A, Carella AM. Atypical clinical presentation of COVID-19: a case of Guillain-Barré

syndrome related to SARS-Cov-2 infection. *Curr Tr Clin Med Sci.* 2020;2:59-67.

9. Toscano G, Palmerini F, Ravaglia S. Guillain-Barré syndrome associated with SARS-CoV-2. *N Engl J Med.* 2020;382:2574-6.
10. Assini A, Benedetti L, Di Maio S, Schirinzi E, Del Sette M. New clinical manifestation of COVID-19 related Guillain-Barré syndrome highly responsive to

intravenous immunoglobulins: two Italian cases. *Neurol Sci.* 2020;41:1657-8.

Cite this article as: Mahur H, Mathur K, Singh DP, Chahar U, Darshan RS, Shivakanth MS. Guillain-Barré syndrome: a rare association of COVID-19 pneumonia at presentation. *Int J Res Med Sci* 2021;9:1201-4.