

Original Research Article

Comparative analysis of correction of idiopathic congenital talipes equinovarus by conventional and accelerated Ponseti method with minimum 12 months follow up in a tertiary care hospital in North India

Pankaj Vir Singh*, Abdul Ghani, Tejpal Singh, Anzar Tariq Malik, Simranpreet Singh

Department of Orthopaedics, GMC, Jammu, Jammu and Kashmir, India

Received: 16 March 2021

Revised: 30 March 2021

Accepted: 31 March 2021

***Correspondence:**

Dr. Pankaj Vir Singh,

E-mail: pankajcoolpal@gmail.com

Copyright: © the author(s), publisher and licensee Medip Academy. This is an open-access article distributed under the terms of the Creative Commons Attribution Non-Commercial License, which permits unrestricted non-commercial use, distribution, and reproduction in any medium, provided the original work is properly cited.

ABSTRACT

Background: Congenital talipes equinovarus (CTEV) is one of the most common congenital anomalies of foot and ankle affecting 1/1000 live birth approximately. With a male dominance pattern, this deformity is bilateral in 50% cases. It has four basic components: cavus, adduction, varus and equinus. Severity of clubfoot is assessed using Pirani score (0 to 6). Insights into the basic pathoanatomy of this complex 3 dimensional deformity has helped to correct it using the method given by Ignacio Ponseti, a Spanish orthopaedician, in which serial manipulations of foot are done and weekly casts are applied, followed by a tendoachilles tenotomy in selected cases to correct the equinus component which is then followed by splintage of the feet in Steenbeek splint initially for 23 hours day for 3 months and then 12 hours a day for 3 years. The most important component of this treatment is parental counselling regarding the need for compliance with treatment which is often loophole responsible for relapse in initially corrected feet.

Methods: This was a prospective study including 40 patients (61 feet) of idiopathic clubfoot with age <3 month at presentation who were randomly distributed in two groups, group 1 (accelerated Ponseti casting group) in which twice weekly casts were applied and group 2 (standard Ponseti casting group) in which weekly casts were applied. Initial Pirani score was calculated in all the patients and was rechecked and documented in every successive visit. All the patients were followed upto 12 months and there was no lost to follow up in this study.

Results: The mean days of plaster duration in accelerated casting group was 18.45 days as compared to 47.25 days in standard casting group (statistically significant, p value <0.05). Also, Pirani score at the end of last follow up was comparable in both the groups. Tenotomy rate was slightly higher in accelerated casting group (89.5%) as compared to standard group (85.7%) which may be attributed to higher initial Pirani score in former (5.5) as compared to later (5.0).

Conclusions: Accelerated biweekly Ponseti casting reduces the overall days of treatment with similar results compared to standard weekly casting regime.

Keywords: CTEV, Accelerated Ponseti casting, Pirani

INTRODUCTION

One among the most common complex congenital anomalies of foot and ankle is congenital talipes equinovarus (CTEV) with an average incidence of one in

every thousand live births.^{1,2} Around 20% of CTEV patients have other associated congenital abnormalities.^{3,4}

With a male to female ratio of 2:1, bilateral deformity is seen in 50% of cases. In unilateral cases, right foot is mostly involved.⁵

In parents already having a child affected with CTEV, there is 10% chance of second child to be affected. There are 30% chances of CTEV in case of monozygotic twins.⁶ CTEV consists of four components: midfoot cavus, forefoot adduction, hindfoot varus and equinus. To achieve a functional, plantigrade foot, enabling the patient to wear usual shoes and to prevent arthritic degenerations in adulthood has been the primary goal of treatment.⁷

With the advancement in understanding of pathoanatomy of the club foot, Ponseti developed a novel method of correction, which has gained wide acceptance worldwide in the last two decades by producing good long-term results.⁸ The standard Ponseti method uses weekly foot and leg plaster changes to gradually correct the deformity, using a strictly defined sequence of moulded plaster changes correcting equinus, adduction, varus and equinus lastly which often requires a percutaneous Tendoachilles tenotomy followed by a final plaster for three weeks. Once plastering is finished, children are placed in a foot-abduction brace with all necessary instructions to parents. The participants in our study were usually from far flung areas and parents had to travel long distance carrying their baby and to keep the plaster dry and prevent it from breakage was a challenge, so this study was undertaken to study and compare the correction achieved by standard weekly Ponseti casting and an accelerated Ponseti casting changing plasters twice weekly.

METHODS

A prospective comparative study of accelerated Ponseti versus the standard Ponseti method for treatment of idiopathic clubfoot was done at Government Medical College, Jammu from a period from February 2020 to October 2020.

A thorough general examination of the child was done so as to detect any associated congenital anomalies of hip and spine. A complete clinical assessment of all feet was made precast and post cast. Parents were educated beforehand about the duration of treatment, expected outcomes and precautions to be observed for children with casts.

Modified Pirani scoring system was used to score the severity of deformity at initial presentation and subsequent visits. Six clinical signs, each scored 0 (normal), 0.5 (mildly abnormal) or 1 (severely abnormal) respectively. Thus, each foot can receive a midfoot score between 0-3 and a hindfoot score between 0-3 and a total score between 0-6. Ponseti method of casting was followed in both standard and accelerated Ponseti groups.

Inclusion criteria

The study included patients with the following criteria: idiopathic CTEV (unilateral/bilateral/male/female); age <3 months; no other associated congenital anomalies; and verbal consent of parents.

Exclusion criteria

The study excluded patients with the following criteria: age >3 months; previously treated CTEV by any method; and atypical CTEV.

A total of 40 patients (61 feet) fitting into inclusion criteria were included in the study and were randomized in two groups: group 1 including those treated by accelerated casting (twice weekly) and group 2 including those treated by standard weekly casting.

There were 19 patients in group 1 (n=19) and 21 patients in group 2 (n=21).

Ponseti casting method

The principle of correction was same as that of Ponseti technique in both the groups. Before application of cast, gentle manipulation of foot for at least one minute was done. Cavus was first corrected by supinating the forefoot, to bring it in line with the hindfoot, and dorsiflexion of the first metatarsal. An above knee cast till groin was applied with knee held in 90 degree of flexion. The toes were exposed to look for any signs of ischemia. In next subsequent visits, manipulation and casting was continued to abduct the foot gradually with head of talus acting as fulcrum. Manipulation and cast was stopped when midfoot and hindfoot scores were zero with 70 degrees of abduction of the forefoot. With abduction of 70 degrees if dorsiflexion was less than 10 degrees then percutaneous tenotomy of the Achilles tendon was performed under local anesthesia as an outpatient procedure and patients were monitored for 1 hour post operatively. A long leg cast was applied in 70 degrees of abduction and maximum available dorsiflexion immediately after tenotomy and maintained for 3 weeks to allow healing of the tendon. After 3 weeks cast was removed and Steenbeek abduction brace was applied. The brace was worn for 23 hours a day for first 3 months after casting and then during night and nap time for 12 hours in a day for 3 years. The length of the bar was equal to the distance between the child's shoulders in every case. Parent self-report on brace wear was used to assess compliance. All children were treated on an outpatient basis to reduce any bias from altered compliance and enabling us to directly compare the efficacy of two methods in terms of correction of the deformity. All patients were followed up till 12 months, on monthly basis for first 4 months and then once every 2 months. Pirani score at final follow up was used to assess the success of treatment in both groups with results being graded as excellent (Pirani score <1), good (score 1-2), and poor (score >2).

RESULTS

A total of 40 patients (61 feet) were included in our study. Out of these 21 cases were bilateral and 19 were unilateral. Patients were randomized into group 1 (n=19, accelerated Ponseti) and group 2 (n=21, conventional weekly Ponseti).

The mean age at presentation was 21 days (7 to 48) in group 1 and 29 days (10 to 55) in group 2. There were 10 male patients (53%) and 9 females (47%) in group 1, and 12 male patients (57%) and 9 female patients (43%) in group 2. The mean Pirani score at the beginning was 5.5 (4.5-6) in group 1 and 5.0 (4-6) in group 2.

17 patients (89.5%) in group 1 underwent tenotomy after correction of cavus, adduction and varus, whereas 18 patients (85.7) in group 2 required tenotomy. Mean duration of treatment from the first cast to tenotomy in group 1 was 18.45 days and in group 2 was 47.25 days, which was statistically significant (p value <0.0001). Patients not needing tenotomy were provided foot abduction brace at this time.

In our study, accelerated group patients needed 6 plasters per foot for correction and standard group 6.35 plasters per foot. The Pirani score at the end of three week plaster post tenotomy showed no significant difference (Pirani score=0-0.5) between the two groups. Data analysis was carried out using STATA software. In order to compare randomized groups for categorical data we used chi-squared tests and Mann-Whitney U tests for continuous variables. P value <0.05 was considered statistically significant.

Comparison of characteristics between randomized groups have been shown in Table 1. Figure 1 shows the comparison in improvement of pirani score from precasting time to the end of follow up at 12 months.

Table 1: Comparison of characteristics between randomized groups.

Variables	Accelerated Ponseti group 1 (n=19)	Standard Ponseti group 2 (n=21)	P value from comparative test
Mean age (days)	21 (7 to 48)	29 (10 to 55)	0.32
Males	10 (53)	12 (57)	0.75
Female	9 (47)	9 (43)	0.69
1 st cast to tenotomy interval (days)	18.45	47.25	0.001
Number of tenotomy	17 (89.5)	18 (85.7)	0.115
Pirani score precast	5.5 (4.5 to 6.0)	5.0 (4.0 to 6.0)	0.143
Pirani score at tenotomy/end of treatment	0.5 (0.5 to 1.0)	0.5 (0 to 1.0)	0.299
Pirani score at 12 months follow up	0 (0 to 1.0)	0 (0 to 0.5)	0.630

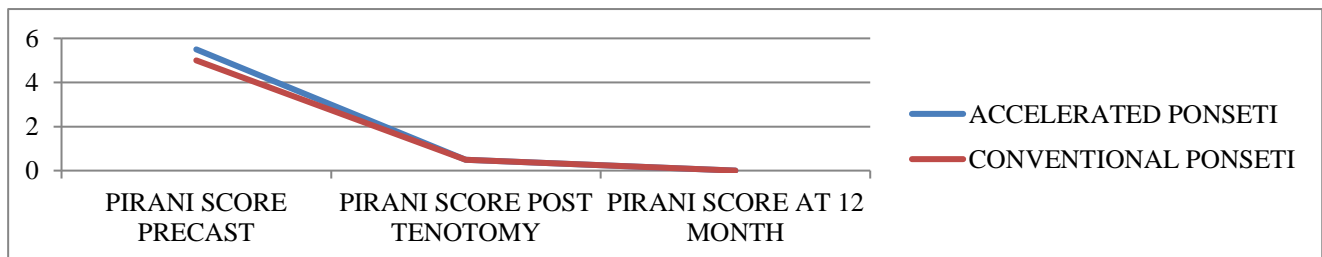


Figure 1: The comparison in Pirani score in both the groups.

Recurrences with different degrees were observed at later follow-up in the form of forefoot adduction, heel varus and equinus, in 3 patients (15.8 %) in the accelerated Ponseti group and 3 patients (14.3) in standard Ponseti group respectively. These relapsed feet were evaluated and completely corrected by either accelerated Ponseti or standard method depending on the assigned group. 2 patients of the accelerated group and 3 patients of the standard group required tenotomy again (Table 2).

Table 2: Relapse rate in both groups and need of second tenotomy.

Casting group	Relapse (%)	2 nd tenotomy
Group 1 (accelerated Ponseti) [n=19]	3 (15.8)	2
Group 2 (conventional Ponseti) [n=21]	3 (14.3)	3

The results were graded as excellent if Pirani score reduced to below 1, good if score was between 1 and 2, and poor if score was >2 at the final follow up.

Accelerated group had excellent results in 17 patients and good results in 2 patients. In the standard group, excellent results were observed in 18 patients and good in 3 patients. None of the patients had poor results. (Table 3).

Table 3: Grading as per Pirani score at 12 month follow up.

Grading	Accelerated group 1	Conventional group 2
Excellent	17 (89.5)	18 (85.7)
Good	2 (10.5)	3 (14.3)
Poor	Nil	Nil
Total	19	21

DISCUSSION

The Ponseti method, which emphasizes manipulation of the foot with serial casting and tenotomy of the Tendoachilles, is currently the method of choice for conservative treatment of clubfoot as has already been proven by many studies.⁹ The conventional Ponseti method involves serial plaster changes at weekly intervals. In a country like India where parents have to travel long distances to bring their children for corrective casting, there are several financial and social issues.¹⁰ There was a slight higher male predominance in our study in both the groups. This is also the result of study done by Solanki et al and Ullah et al.^{11,12} There was a slightly higher rate of tenotomy in accelerated group (89.5%) as compared to conventional group (85.7%) but this was not statistically significant (p value=0.115). This can be attributed to higher initial mean Pirani score in accelerated group (5.5) as compared to conventional group (5.0). This characteristic was identified by Scher et al who related higher Pirani scores to the need for a tenotomy.¹³ The number of days required for the correction in plaster were 18.45 days in case of accelerated group and 47.25 days in case of conventional group, this was a statistically significant difference (p value=0.001). Same was the result obtained by various studies (Table 4). However Pirani score at the end of follow up in both the groups showed almost similar results in terms of plantigrade, functional and cosmetically accepted foot.

Table 4: Various studies comparing the average number of days in plaster for accelerated versus conventional Ponseti method.

Studies	Accelerated group (days)	Conventional group (days)	P value
Morcuende et al ¹⁴	16	24	<0.05
Xu RJ ¹⁵	20.61	35.35	<0.05
Harnett et al ¹⁶	16	42	<0.05
Sharma et al ¹⁷	15	35	<0.05
Present study	18.45	47.25	<0.05

Relapse following correction usually occur in the order of hindfoot equinus, heel varus, forefoot adduction and cavus occurs at last. There were 3 cases of relapse in both the groups following correction. The most significant factor with regard to recurrence during follow-up is compliance with the abduction brace.¹⁴ Haft, Walker and Crawford reported a five times greater chance of recurrence in patients whose parents were noncompliant with bracing.¹⁸ With studies which have showed a positive correlation between compliance with bracing and incidence of relapse, the earlier introduction of patients into bracing phase might be more beneficial than as thought.^{19,20} Such relapses can be decreased by parental counselling at each

successive visit and explaining them the need to wear abduction brace.

The strengths of our study are that it's a prospective study with minimum 12 months follow up and no patient was lost during follow up period. The limitations are that it's a non-randomized study with a small sample size. Our study compared the clinical outcomes of idiopathic clubfoot in child <3 month age using accelerated (biweekly) casting and standard weekly casting, and showed the efficacy of accelerated casting over standard casting in terms of shorter days to correction with a comparable Pirani score at the end of follow up.

CONCLUSION

Keeping in view the psychological and economic burden over the family of the patient with club foot travelling long distances to the location of treatment centre (mostly the tertiary care hospital) it has become a necessity to shorten the time required for deformity correction for the convenience of both the patient and the parents. Using accelerated Ponseti casting, there is significant reduction in duration of treatment days with similar results at the end of follow up when compared to conventional casting. It will also decrease the concerns regarding problem of plaster slippage and help to improve overall compliance among parents. Accelerated casting can reduce the overall economic burden on the poor patients by reducing the number of days of work lost as well as the total expenditure on the travel. We hope that this will provide a useful alternative, particularly for patients who have to travel long distances for treatment and for those who find it difficult to comply with weekly plaster treatment.

Funding: No funding sources

Conflict of interest: None declared

Ethical approval: The study was approved by the Institutional Ethics Committee

REFERENCES

1. Wynne-Davies R. Genetic and environmental factors in the etiology of talipes equinovarus. Clin Orthop Rel Res. 1972;84:9-13.
2. Azar FM, Canale ST, Beaty JH. Campbell's Operative Orthopaedics, 13th edition, Elsevier. 2017.
3. Siapkara A, Duncan R. Congenital talipes equinovarus: a review of current management. J Bone Joint Surg [Br]. 2007;89-B:995-1000.
4. Chung CS, Nemechek RW, Larsen IJ, Ching GH. Genetic and epidemiological studies of clubfoot in Hawaii: general and medical considerations. Hum Hered. 1969;19:321-42.
5. Clubfoot VJT. Current problems in Orthopaedics New York: Churchill Livingstone. 1981.
6. Agrawal RA, Suresh MS, Agrawal R. Treatment of congenital club foot with Ponseti method. Indian J Orthop. 2005;39:244-7.

7. Cosma DI, Vasilescu DE. Ponseti treatment for clubfoot in Romania: a 9- year single-centre experience. *J Pediatr Orthop.* 2014;23(6):512-6.
8. Ponseti IV. Treatment of congenital club foot. *J Bone Joint Surg Am.* 1992;74:448-54.
9. Cooper DM, Dietz FR. Treatment of idiopathic clubfoot. A thirty year follow up note. *J Bone Joint Surg Am.* 1995;77:147789.
10. Macnicol MF. The management of club foot: Issues for debate. *J Bone Joint Surg Br.* 2003;85:16770.
11. Solanki M, Ajmera A, Rawat S. Comparative study of accelerated ponseti method versus standard Ponseti method for the treatment of idiopathic clubfoot. *J Orthop Traumatol Rehabil.* 2018;10:116-9.
12. Ullah S, Inam M, Arif M. Club foot management by accelerated Ponseti technique. *RMJ.* 2014;39:41820.
13. Scher DM, Feldman DS, van Bosse HJ, Sala DA, Lehman WB. Predicting the need for tenotomy in the Ponseti method for correction of clubfeet. *J Pediatr Orthop.* 2004;24:34952.
14. Morcuende JA, Abbasi D, Dolan LA, Ponseti IV. Results of an accelerated Ponseti protocol for clubfoot. *J Pediatr Orthop.* 2005;25:623-6.
15. Xu RJ. A modified Ponseti method for the treatment of idiopathic clubfoot: a preliminary report. *J Pediatr Orthop.* 2011;31(3)317-9.
16. Harnett P, Freeman R, Harrison WJ, Brown LC, Beckles V. An accelerated Ponseti versus the standard Ponseti method: a prospective randomised controlled trial. *J Bone Joint Surg Br.* 2011;93(3):404-8.
17. Sharma P, Yadav V, Verma R, Gohiya A, Gaur S. Comparative analysis of results between conventional and accelerated Ponseti technique for idiopathic congenital clubfoot. *Orthop J.* 2016;22:37.
18. Haft GA, Walker CG, Crawford HA. Early clubfoot recurrence after use of the Ponseti method in a New Zealand population. *J Bone Joint Surg [Am].* 2007;89-A:487-93.
19. Giesberts RB, Van der Steen MC, Maathuis PGM, Besselaar AT, Hekman EEG, Verkerke GJ. Influence of cast change interval in the Ponseti method: A systematic review. *PLoS One.* 2018;13(6):e0199540.
20. Garg S, Porter K. Improved bracing compliance in children with clubfeet using a dynamic orthosis. *J Child Orthop.* 2009;1:271-6.

Cite this article as: Singh PV, Ghani A, Singh T, Malik AT, Singh S. Comparative analysis of correction of idiopathic congenital talipes equinovarus by conventional and accelerated Ponseti method with minimum 12 months follow up in a tertiary care hospital in North India. *Int J Res Med Sci* 2021;9:1296-300.