

## Original Research Article

# Functional outcome of long proximal femoral nail versus short proximal femoral nail in peritrochanteric fractures

Sanjeev Gupta, Pallav Gupta, Gagandeep Singh Raina\*, Manoj Kumar, Gagandeep Singh

Department of Orthopaedics, Government Medical College, Jammu, Jammu and Kashmir, India

**Received:** 20 March 2021

**Accepted:** 05 April 2021

### \*Correspondence:

Dr. Gagandeep Singh Raina,  
E-mail: [gsraina67@gmail.com](mailto:gsraina67@gmail.com)

**Copyright:** © the author(s), publisher and licensee Medip Academy. This is an open-access article distributed under the terms of the Creative Commons Attribution Non-Commercial License, which permits unrestricted non-commercial use, distribution, and reproduction in any medium, provided the original work is properly cited.

## ABSTRACT

**Background:** Proximal femoral nail (PFN) is an intramedullary implant which has been commonly used in the fixation of intertrochanteric fractures. However, controversy comes about the effect of nail length on fracture union and other complications. A comparative evaluation of surgical treatment and functional outcome of patients with peritrochanteric fractures treated with short versus long PFN.

**Methods:** Total of 100 patients have been included in study out of which 57 belonged to group 1 and were operated with short PFN and rest 43 were group 2 operated with long PFN. Patients were followed up for 6 months and were compared on various parameters.

**Results:** There is no significant difference noted in the two group. However, the surgical duration and blood loss for short PFN was significantly less as compared to long PFN.

**Conclusions:** Short PFN is better implant for peritrochanteric fractures both stable and unstable with quicker surgical time and lesser blood loss.

**Keywords:** Peritrochanteric fractures, PFN, Short, Long, Intermedullary fixation

## INTRODUCTION

Peritrochanteric fractures of femur account for nearly half the hip fractures in elderly patients. With the aging of population and increase in life expectancy, osteoporosis has come up as a major health problem which in turn has led to increased incidence of hip fractures in this age group.<sup>1</sup> It has been estimated that in 2050, there will be 6.3 million hip fractures in the elderly and about half of these will be intertrochanteric fractures, which will have significant contribution to health problems and mortality.<sup>2</sup> As per reports, 20 to 30% elderly patients of peritrochanteric fractures will die within six to 12 months of injury.<sup>3</sup> Proximal femoral intramedullary nails have been commonly used in the fixation of intertrochanteric fractures. However, controversy comes about the effect of nail length on fracture union and other complications. Short PFN has a good bio-mechanical stability and acceptable clinical outcome. However, there are studies

that states that the use of short nail increases the stress at the nail tip making patient liable to periprosthetic fractures.<sup>4</sup>

The goal of treatment of any fracture fixation is restoration of the patient to his or her pre-injury condition as soon as possible. This factor leads to decision of internal fixation of these fractures to increase patient comfort, decrease hospital stay and avoid the complications of prolonged recumbency.<sup>5</sup> Intramedullary implants like the PFN have an advantage in such fractures as their placement allows the implant to lie closer to the mechanical axis of the extremity, which decreases the lever arm and bending moment on the implant. Intramedullary nailing, with less operative blood loss and less operative time allow early weight bearing with less resultant shortening on long term follow up.<sup>6</sup> This study was aimed to investigate the efficacy of short and long proximal femur nail by comparing blood loss,

operation time, postoperative complications, periprosthetic fracture and patient outcomes.

## METHODS

A prospective study was conducted in our institute between January 2019 To July 2020 after seeking approval from IEC. The patients were followed up for period of six months

The study was carried out in the department of orthopaedics at our institute. Total of 100 patients have been included in study out of which 57 belonged to group 1 and were operated with short PFN and rest 43 were group 2 operated with long PFN. Both the groups included patients with peritrochanteric fractures (intertrochanteric fractures with maximum of 3 cm extension below lesser trochanter).

### Exclusion criteria

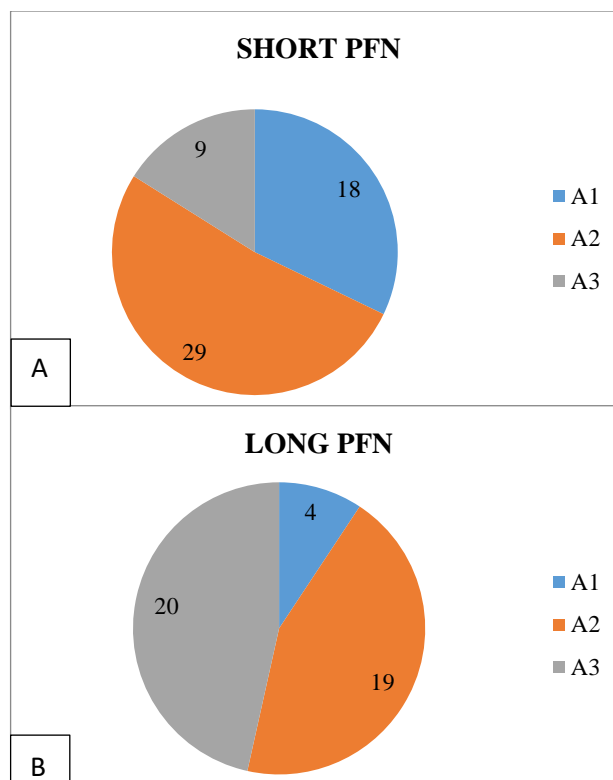
Exclusion criteria for study excluded patients with compound and pathological fractures, patients with disorders of bone metabolism other than osteoporosis or any other co-morbidity that makes them unfit for surgery and <18 years of age. Patient with any other fractures. And low subtrochanteric fractures 3 cm below lesser trochanter.

Patients were operated as soon as the medical conditions allowed and fit for anaesthesia. We used pre-operative (prophylactic) antibiotics in all the cases. Patients were maintained pain free by use of analgesics like NSAIDs, opioid analgesics for initial few days and thereafter as and when required. All the other patients were allowed to sit up on the bed within 24 hours. They were taught quadriceps strengthening exercises and were made to walk with assistance next day. Patients were made to ambulate as early as possible to prevent DVT and pressure sores. Most of the patients were discharged on 5<sup>th</sup> or 7<sup>th</sup> post op day after assisted ambulation with help of walker. Patients were called for follow up after 1 week for stitch removal and subsequently after 2 weeks, 1 month and then next month up to six months.

Data was compiled and statistical values like range, mean and percentage were evaluated and comparison was done between both groups.

## RESULTS

100 patients went for surgery for peritrochanteric fracture during the period of study. The patient characteristics of both groups was not significantly different. AO 31-A1 and A2 were most common type of fractures in both groups. Out of 57 patients in group 1, 18 cases were AO 31A1 type, 29 were A2 and 9 patients were A3 type. In group 2, out of 43 patients, 20 were A3 type, 19 cases were A2 and only 4 cases were A1 (Figure 1).



**Figure 1: (A and B) Number of cases in each group and their distribution as per AO classification.**

**Table 1: Patient statistics.**

Parameter	Long PFN	Short PFN
Average age (years)	65.3	70.5
Average blood loss (ml)	150	100
Average operating time (min)	64.3	43.6
Union (weeks)	14.	15.1
Harris hip score	85.43	82.33
Thigh pain (%)	4.5	13

Majority patients in both the groups were above the age of 50 and sustained injury due to low energy trauma. Average age of the patient treated with short PFN was 70.5 while that with long PFN was 65.3 years. The average blood loss during the surgical procedure of short PFN was 100 ml while that in long PFN was 150 ml. In short PFN group, patients had operative time (from incision to closure) of 30-50 minutes with average of 43.6 minutes whereas in long PFN operative time was 45-90 minutes with average of 64.3 minutes. In post-operative period there was no significant difference. Two cases of short PFN and one case of long PFN had serous discharge and soakage which eventually resolved with change of antibiotics. Later both the groups were evaluated in post op period and at 3<sup>rd</sup> month to compare the outcome. The radiological signs of union were present in almost all the patients at 3±1 month. The Harris hip score was calculated for both the groups at 3 and 6 months and

mean HHS for short PFN was 76.63 and 82.33 whereas for long PFN average score was 79.87 and 85.43 at 3 and 6 months respectively. Few patients also complained of thigh pain which included 7 patients (13%) of short PFN and 2 patients (4.5%) of long PFN. During 3 months of follow up, implant related complication was seen in one patient of short PFN (infected implant with loosening of proximal screw) and 1 patient of long PFN group (lag screw cut out) (Table 1).

## DISCUSSION

Hip fractures are a serious cause of concern in the osteoporotic elderly population. The associated mortality and morbidity with hip fractures is significant. In present study, patients who underwent short PFN had lesser bleeding and operating time. Long PFN leads to more reaming and opening of canal and hence more bleeding and greater operating time leads to higher chances of infection. Moreover, distal locking of long PFN is done by free hand technique and hence more bleeding and stress and trauma to bone and more operative time. This is similar to results of Guo et al the intraoperative blood loss was (90.7±50.6) ml in short nail group, greatly less than that in long nail group (127.8±85.9) ml.<sup>1</sup> The short nail group also had a significantly shorter operation time (43.5 min±12.3 min vs. 58.5 min±20.3 min).<sup>1</sup> Average time of union in our study is 14.2 weeks for long PFN and 15.1 weeks for short PFN with average time of union 14.7 weeks. The average radiological time of union in studies of Harrington et al, Rao et al and Mall et al were 16 weeks, 18 weeks and 14 weeks respectively.<sup>7-9</sup> Post-operative outcome of both nails was however similar with comparative time to union and Harris hip score which is in line with results of Kale et al who state no statistically significant differences between these groups in Harris hip score at 1 year postoperatively and study by Shyamkumar which reported almost similar HHS in long (79.33) and short (77.30) PFN.<sup>10,11</sup> More patients (7) treated with short PFN reported thigh pain than long PFN (2) which may be attributed to the shorter working length of PFN and narrow proximal canal which puts more stress on the proximal femoral shaft cortices. Similar results were obtained in study of Shyamkumar where high pain in all patients of long and most patients (5) of short PFN was eventually resolved with time and medication.<sup>11</sup>

## Limitations

The limitations of this study include small sample size and duration of follow up.

## CONCLUSION

Both long and short PFN provide rigid fixation for inter trochanteric fractures. Both the implants have almost same functional outcome. In intertrochanteric fractures with fracture line up to lesser trochanter (AO 31A1 and A2), short PFN is definitely better implant due to less blood loss and less operating time. However, in patients

with sub trochanteric extension (more than 3 cm) and severe osteoporosis, long PFN provides more rigid fixation and less chances of refracture.

*Funding: No funding sources*

*Conflict of interest: None declared*

*Ethical approval: The study was approved by the Institutional Ethics Committee*

## REFERENCES

1. Guo XF, Zhang KM, Fu HB, Cao W, Dong Q. A comparative study of the therapeutic effect between long and short intramedullary nails in the treatment of intertrochanteric femur fractures in the elderly. *Chin J Traumatol.* 2015;18:332-5.
2. Melton LJ 3<sup>rd</sup>, Gabriel SE, Crowson CS, Tosteson AN, Johnell O, Kanis JA. Cost-equivalence of different osteoporotic fractures. *Osteoporos Int.* 2003;14:383-8.
3. Brauer CA, Coca-Perrillon M, Cutler DM, Rosen AB. Incidence and mortality of hip fractures in the United States. *JAMA.* 2009;302(14):1573-9.
4. Krishnan BH, Rai SK, Vikas R, Kashid M, Mahender P. A comparative study of the fracture union between long and short proximal femoral intramedullary nails anti-rotation in the treatment of intertrochanteric femur fractures in the elderly: a multicentric analysis. *Int J Res Orthop.* 2019;5:288-94.
5. Cooper AP. A Treatise on dislocations and fractures of the joints. London, England: Longman, Hurst, Rees, Orme and Brown. 1822.
6. Boldin C, Seibert FJ, Fankhauser F, Peicha G, Grechenig W, Szyszkowitz R. The proximal femoral nail (PFN)-a minimal invasive treatment of unstable proximal femoral fractures: a prospective study of 55 patients with a follow-up of 15 months. *Acta Orthop Scand.* 2003;74(1):53-8.
7. Harrington KD, Johnson JO. The management of comminuted unstable intertrochanteric fractures *JBJS.* 1973;55A:1367.
8. Rao JP, Banzon MT, Wiess TB. Treatment of unstable intertrochanteric fracture with anatomic reduction and compression hip screw. *Clin Orthop related res.* 1983;175:65-78.
9. Mall B, Pathak SK, Malhotra V. Role of dynamic compression hips screw in trochanteric fracture of femour. *Indian J Orthop.* 1999;33(3):226-8.
10. Kale A, Munde D, Mangukiy HJ, Waghmare V. A comparative study of long versus short proximal femoral nail in peritrochanteric and subtrochanteric fractures in adults. *Int J Orthop Sci.* 2018;4(2):717-21.
11. Shyamkumar CMS. Comparative Study between Long PFN And Short PFN in Treatment of Stable Intertrochanteric Fracture Femur. *J Dental Med Sci.* 2018;17(1):23-9.

**Cite this article as:** Gupta S, Gupta P, Raina GS, Kumar M, Singh G. Functional outcome of long proximal femoral nail versus short proximal femoral nail in peritrochanteric fractures. *Int J Res Med Sci* 2021;9:1479-81.