

Case Report

Pancreatic cancer in obstructive jaundice in unexpected age

Karmen Bahnam Katay*, Reem Hamed Khamis, Thafar Salim Al Safar

Family Medicine, Al Thummama Health Centre, Primary Health Care Corporation, Doha, Qatar

Received: 05 April 2021

Revised: 09 May 2021

Accepted: 10 May 2021

*Correspondence:

Dr. Karmen Bahnam Katay,
E-mail: thafar_alsafar@yahoo.com

Copyright: © the author(s), publisher and licensee Medip Academy. This is an open-access article distributed under the terms of the Creative Commons Attribution Non-Commercial License, which permits unrestricted non-commercial use, distribution, and reproduction in any medium, provided the original work is properly cited.

ABSTRACT

Cancer of the pancreas is a highly lethal malignancy. It is considered as the fourth leading cause of cancer-related death in the United States and second only to colorectal cancer as a cause of digestive cancer-related death. It is hoped that detection of asymptomatic and early stage of disease is potentially curable pancreatic cancer and it will improve outcomes. Our case report is 45 years old female who presented at our primary health care centre with obstructive jaundice for only 2 weeks and no weight loss, vague abdominal pain. She had intermittent epigastric pain for past few months and diagnosed as gastroesophageal reflux. Also, she had chronic anemia and need blood transfusion in the past 3 years. No family history of pancreatic cancer and no other risk factor. Most articles reveal difficulty in diagnosing pancreatic cancer in early stage and young age group due to its resemblance to benign lesion. That's why we prefer to do case report for documentation. Diagnosis of the tumor is important especially in early stages for improving prognosis.

Keywords: Pancreatic cancer, Obstructive jaundice, Early detection

INTRODUCTION

Through out the world, the cancer of the pancreas is the seventh leading cause of deaths due to cancer in both men and women according to data from the world health organization (WHO) GLOBOCAN database and data from the 2017 global burden of disease study.¹⁻³

Regrettably, due to late presentation, only 15 to 20% of patients are eligible for pancreatectomy which led to poor prognosis, even after complete resection.⁴

The disease is rare before the age of 45, but the incidence rises sharply thereafter. In data from the Global Burden of Disease Study, the number of incident cases peaked at age 65 to 69 for men and at 75 to 79 for women.²

General speaking, pancreatic cancer affects more individuals living the Western/industrialized area of the world; the highest incidence is reported in high-income

people in North America and, in the other hand people inhabiting in South Asia and eastern Asia have the lowest reported incidence.²

Furthermore, the incidence of pancreatic cancer and death rates alter by gender and race.⁵ The incidence is higher in males gender than in females (the ratio of male:female is 1.3:1) and more in black skin than in white skin (16.7 per 100,000 for black men in comparison to 14.8 per 100,000 for white women).⁶

Some environmental risk factors could be related to increase the risk of pancreatic cancer. One of them is cigarette smoking which contribute to elevate the risk for pancreatic cancer.^{7,8} Another risk is obesity and lack of physical activity.⁹ In the other hand alcohol consumption is increase risk in small and limited to heavy drinkers.¹⁰

Considerable epidemiologic analysis revealed an association between diabetes mellitus and pancreatic cancer.¹¹

One of the important risk factor is the family history of genetic liability to pancreatic cancer, some studies shows that cancer of pancreas clumps in some families; about 5 to 10 percent of people with pancreatic cancer have a family history of the disease. There are wide categories of hereditary risk for cancer of pancreas defined as syndromes like hereditary breast and ovarian cancer syndrome BRCA: breast cancer susceptibility gene; familial pancreatic cancer (pancreatic ductal adenocarcinoma); Peutz-Jeghers syndrome.^{12,13}

Pancreatic cancer typically does not cause symptoms until it has grown, so it is most frequently diagnosed in advanced stages rather than early in the course of the disease.

Most common presentation is painless obstructive jaundice (The differential diagnosis list of the jaundiced is wide; sorting of jaundice depend on the kind of bile pigment "bilirubin" and the mechanism causing hyperbilirubinemia), weight loss and vague abdominal symptoms also are characteristic.¹⁴ More than one half of cases have distant metastasis at the time of diagnosis

While jaundice can be a symptom at any stage of pancreatic cancer, when pancreatic cancer is diagnosed early, patients may be eligible for surgery, which offers the best chance for long-term control of the disease.¹⁵

CASE REPORT

A 45 years old Filipino female patient presented to the primary health care center in April 2020 complain from dark color urine noticed approximately 2 weeks ago followed by yellowish discoloration of her eyes since the last 5 days, with upper abdominal pain on left side 5 days prior to presentation but resolved in last 2 days, she noticed as well that her stool become paler than before 2 days. in addition to loss of appetite since the onset of her symptoms with weight loss of 2 kg.

The urinary symptoms not associated with burning or pain or change in frequency. The yellowish eyes discoloration is progressively worsening, and the upper abdominal pain is intermittent, mild, non-radiating (she already has chronic intermittent epigastric pain of GERD for the past few months).

Denied any fever, nausea, vomiting, itching, rashes and joints pain.

She had past medical history of gastro esophageal reflux (GERD) and chronic iron deficiency anemia for the past 3 years which required blood transfusion at least once in a year due to menorrhagia (heavy period) as diagnosed before by gynecologist consultation

She had past surgical history of benign breast cyst has been removed.

After review her family history, her aunt has anemia that requiring blood transfusion but no gastrointestinal tract illnesses.

Her social history shows she smokes 3-4 cigarette/day for the past 1 year. On presentation she was on iron, folic acid and cyanocobalamin tablets.

On examination her vitals were normal she had pale, yellowish discoloration of sclera icteric and the body (generalized jaundice). With soft abdomen not distended, no specific tenderness no palpable mass or organomegaly normal bowel sounds. With normal other system examination.

Her initial Laboratory investigation shows in Table 1.

Table 1: Laboratory investigation result with normal range and comments.

Laboratory test	Level	Normal range	Comment
WBC (uL)	6 x10 ³	4-10	Normal
Hgb (gm/dl)	7.9	12.0-15.0	Low
MCV (fL)	53.3	83-101.0	Low
MCHC (gm/dl)	29.4	27.0-32.0	Normal
Serum Iron	3.68	12.0-240.0	Low
TIBC (umol/L)	96	45-80	High
Transferrin (gm/dl)	3.82	2-3.6	High
Ferrous saturation ()	4	15-45	Low
Platelet (uL)	227 x10 ³	150-400	Normal
Prothrombin time:	15.3	9.4-12.5	Prolonged
APTT	31.1	24.6- 31.2	Normal
INR	1.3	Critical high >4.9	Normal
Total bilirubin	139.9	3.4-20.5	High
Direct bilirubin	82.6	0-8.6	High
Protein (gm/L)	77	66-87	Normal
Albumin (gm/L)	39	35-52	Normal
Alkaline phosphatase	935.5	40-150	High
ALT	290.3	0-55	High
AST	163	0-34	High
Lipase (U/L)	208	8-78	High
Creatinine (umol/L)	40.0	44-80	Normal
Urea (mmol/L)	1.98	2.8-8.1	Normal
Hepatitis B surface antigen	Negative		
Hepatitis B core antibodies	Negative		
Hepatitis C antibodies	Negative		
hepatitis A antibodies	Negative		

She had low hemoglobin with low MCV, low MCHC, low serum iron and high TIBC. Her white blood cell (WBC) and platelet was normal.

Her total bilirubin and direct bilirubin was high with normal protein and albumin level.

She had high liver enzymes like alkaline phosphatase, ALT, AST and lipase. Her renal function and electrolyte test was normal.

Her viral hepatitis serology shows negative for hepatitis B virus, hepatitis C virus and hepatitis A virus infection (including hepatitis B surface antigen, hepatitis B core antibodies, and hepatitis C antibodies, hepatitis A antibodies.)

Urine analysis-dark yellow color, leukocyte in urine:+++, bilirubin in urine+++, urobilinogen; normal, and negative urine for protein, glucose, ketones and nitrite.

Urgent abdominal ultrasound findings were intrahepatic biliary ductal dilatation, common bile duct (CBD) and pancreatic duct dilatation, no cholelithiasis in gallbladder, there is suspected isoechoic well defined pancreatic mass at the pancreatic head (suggesting pancreatic neoplasm). Spleen, both kidneys and urinary bladder are unremarkable. No enlarged mesenteric lymph nodes noted, no intraperitoneal fluid detected, chest x-ray was normal.

Later patient was called and was referred to surgery department in hospital as a case of highly suspected pancreatic cancer.

In hospital they did tumor marker for her CA19 was 224 high (normal 0-27) and CEA was 3.1 normal (normal range 3.8-5.0).

She did Magnetic resonance cholangiopancreatography (MRCP) with contrast shows Focal lingulae infiltrative mass lesion involving the head of the pancreas with and without cut-off of the distal CBD with moderate intra and extrahepatic ductal dilatation with pancreatic duct dilatation and mild pancreatic atrophy. (Figure 1: A and B), (Figure 2: A and B).

Findings are concerning for neoplastic lesion. further assessment with endoscopic biopsy and histopathologic correlations suggested.

Then endoscopic ultrasound or echo-endoscopy (EUS) (Figure 3 (A and B) shows hypoechoic mass lesion in the pancreatic head, it has irregular margin and measured 30x37 mm in diameter.

Finally, she did positron emission tomography (PET) report shows an intense hypermetabolism in pancreatic head lesions highly suspicious of malignancy. No PET sign of lymph nodes or distant metastasis was found. Small right lung nodules with likely benign background.

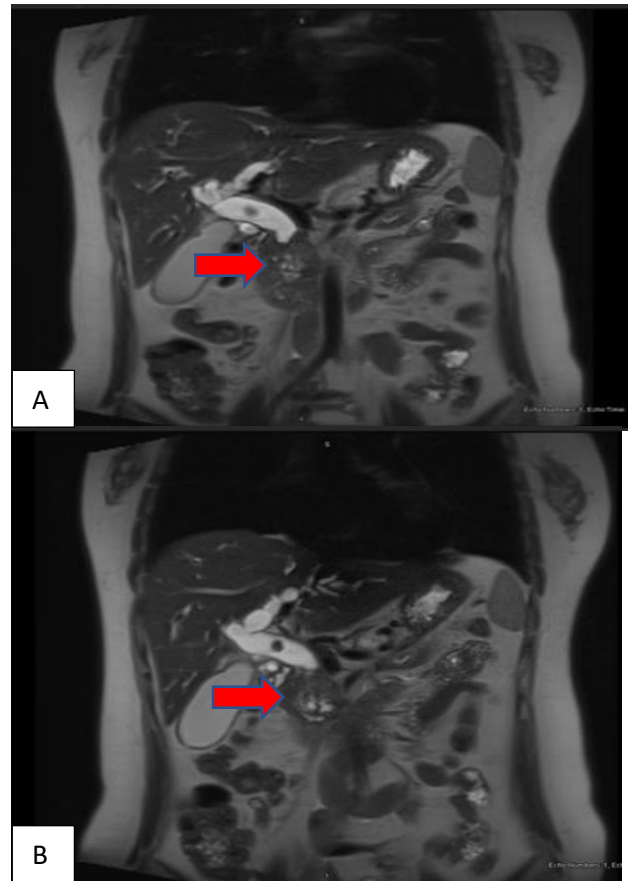


Figure 1: (A and B) MRCP images (vertical section) of mass lesion involving the head of the pancreas.

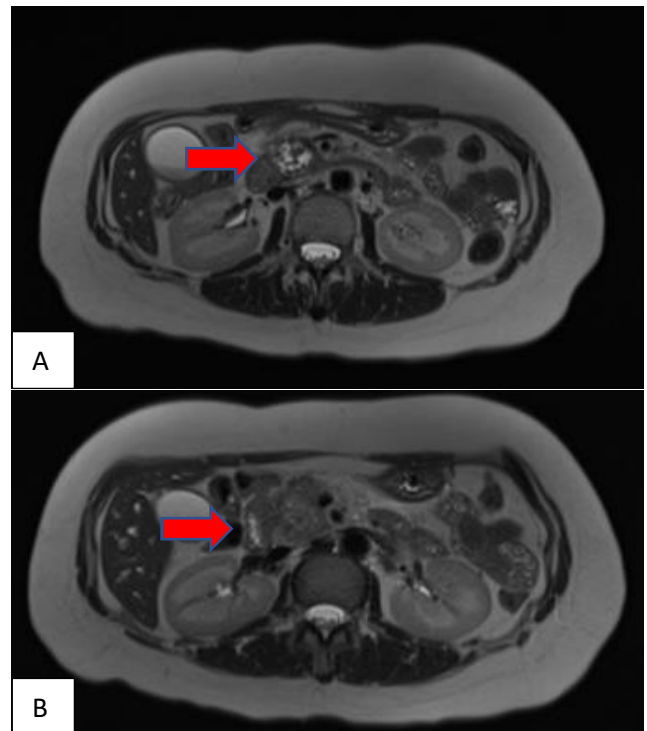


Figure 2: (A and B) MRCP images (cross sectional) of pancreatic mass.

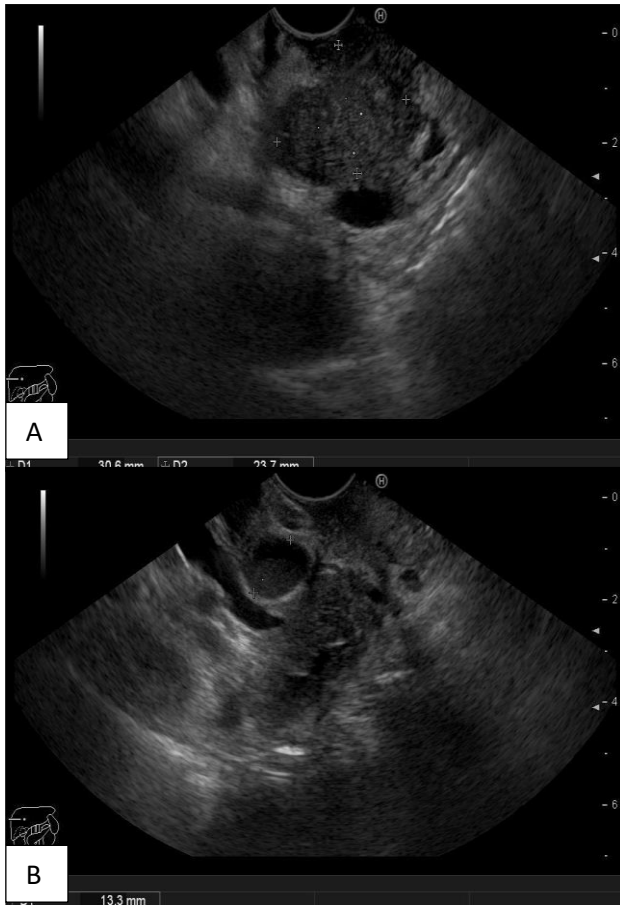


Figure 3: (A and B) images of EUS.

Management plan

She did Whipple pancreaticoduodenectomy (resection of head of pancreatic mass), the histopathology shows The Pancreatic main specimen for pancreas margin: shows moderately differentiated adenocarcinoma while Peripancreatic fat shows Benign fibroconnective tissues. Common bile duct (CBD) margin, Hilar lymph nodes, mesenteric lymph node all negative for malignancies, gall bladder shows Chronic cholecystitis.

Her pathologic staging was: pT3 N1 no metastasis and she need only adjuvant chemotherapy after above surgery.

When NM whole body FDG PET CT repeated on December 2020 after surgery shows no evidence of recurrence.

DISCUSSION

Pancreatic carcinoma is one of the most aggressive malignancies with overall 5-year survival below 5%.¹⁵ Mainstays curative treatment for pancreatic carcinoma is surgery which is possible in less than 20% of patients depends on staging.

The rarity of our patient that she was only 45 years old at time of diagnosis, although most people who develop pancreatic cancer are older than 45 in fact, 90% are older than 55 and 70% are older than 65.² However, adult of any age can be diagnosed with pancreatic cancer. Also, our patient is female and pancreatic cancer more in male.⁵ Moreover she is Filipino, not belonging to western country as studies mention pancreatic cancer is more in western country and less in south Asian countries.²

She does not have family history of genetic liability to pancreatic cancer which studies show is strong related.⁶ Also she is not diabetic.¹¹

The primary differential diagnosis includes other causes of obstructive jaundice like gall bladder stones, obstruction of biliary due to other tumors either malignant or adenomas, intrahepatic cholestasis, chronic or acute hepatocellular injury like viral hepatitis and blood dyscrasia.¹⁴

The early diagnosis of patient is reflecting in prognosis, management plan and recurrence of disease.

CONCLUSION

The presentation of our patient highlights the importance of awareness of early symptoms of pancreatic cancer, early diagnoses and the need for further research in developing an effective screening methodology. This suggests as well that in the setting of primary care, it is beneficial for practitioners to maintain a high index of suspicion for pancreatic cancer. Add that this case came to primary care first during COVID-19 pandemic when most of physician concentrations on covid 19 presentations and there is limitation of face-to-face consultation.

Recommendation

Author's recommendation, is to investigate any patient presented with epigastric pain for long time in addition to weight loss by transabdominal ultrasound (US) initially to estimate bile ducts for dilation or a pancreatic mass. To find a way for screening for early detection of pancreatic cancer, despite it is currently restricted to high-risk people who have familial syndromes predisposing them to cancer of pancreas. Early detection is vital for surgical decision, management plan and prognosis of disease.

Funding: No funding sources

Conflict of interest: None declared

Ethical approval: Not required

REFERENCES

1. Siegel RL, Miller KD, Jemal A. Cancer statistics, 2020. *CA Cancer J Clin.* 2020;70:7.
2. GBD 2017 Pancreatic Cancer Collaborators. The global, regional, and national burden of pancreatic

cancer and its attributable risk factors in 195 countries and territories, 1990-2017: a systematic analysis for the Global Burden of Disease Study 2017. *Lancet Gastroenterol Hepatol.* 2019;4:934

3. Blackford AL, Canto MI, Klein AP. Recent Trends in the Incidence and Survival of Stage 1A Pancreatic Cancer: A Surveillance, Epidemiology, and End Results Analysis. *J Natl Cancer Inst.* 2020;112:1162.
4. Allen PJ, Kuk D, Castillo CF. Multi-institutional Validation Study of the American Joint Commission on Cancer (8th Edition) Changes for T and N Staging in Patients with Pancreatic Adenocarcinoma. *Ann Surg.* 2017;265:185.
5. Zhang J, Dhakal I, Ning B, Kesteloot H. Patterns and trends of pancreatic cancer mortality rates in Arkansas, 1969-2002: a comparison with the US population. *Eur J Cancer Prev.* 2008;17:18.
6. Howlader N, Noone AM, Krapcho M, Miller D. SEER Cancer Statistics Review, 1975-2016, National Cancer Institute. Bethesda Available at: https://seer.cancer.gov/csr/1975_2016/, based on November 2018 SEER data submission, posted to the SEER web site, April 2019. https://seer.cancer.gov/csr/1975_2017/. Accessed on April 01, 2021.
7. Rebours V, Lévy P, Ruzsiewicz P. An overview of hereditary pancreatitis. *Dig Liver Dis.* 2012;44:8.
8. Lowenfels AB, Maisonneuve P, Whitcomb DC. Risk factors for cancer in hereditary pancreatitis. *International Hereditary Pancreatitis Study Group. Med Clin North Am.* 2000;84:565.
9. Carreras-Torres R, Johansson M, Gaborieau V. The Role of Obesity, Type 2 Diabetes, and Metabolic Factors in Pancreatic Cancer: A Mendelian Randomization Study. *J Natl Cancer Inst.* 2017;109.
10. Lucenteforte E, La Vecchia C, Silverman D. Alcohol consumption and pancreatic cancer: a pooled analysis in the International Pancreatic Cancer Case-Control Consortium (PanC4). *Ann Oncol* 2012; 23:374.
11. Huxley R, Ansary-Moghaddam A, Berrington de González A, et al. Type-II diabetes and pancreatic cancer: a meta-analysis of 36 studies. *Br J Cancer* 2005; 92:2076.
12. Klein AP, Hruban RH, Brune KA. Familial pancreatic cancer. *Cancer J.* 2001;7:266.
13. Olson SH, Kurtz RC. Epidemiology of pancreatic cancer and the role of family history. *J Surg Oncol.* 2013;107:1.
14. Kalser MH, Barkin J, MacIntyre JM. Pancreatic cancer. Assessment of prognosis by clinical presentation. *Cancer.* 1985;56:397.
15. Manabe T, Miyashita T, Ohshio G. Small carcinoma of the pancreas. Clinical and pathologic evaluation of 17 patients. *Cancer.* 1988;62:135.

Cite this article as: Katay KB, Khamis RH, Al Safar TS. Pancreatic cancer in obstructive jaundice in unexpected age. *Int J Res Med Sci* 2021;9:1765-9.