

## Case Report

# Effect of post-operative physiotherapy intervention following decortication and bullectomy: a case report

Titiksha T. Pol\*

School of Physiotherapy, DY Patil University, Nerul, Navi Mumbai, Maharashtra, India

**Received:** 08 April 2021

**Revised:** 07 May 2021

**Accepted:** 10 May 2021

### \*Correspondence:

Dr. Titiksha T. Pol,

E-mail: [titikshapolphysio@gmail.com](mailto:titikshapolphysio@gmail.com)

**Copyright:** © the author(s), publisher and licensee Medip Academy. This is an open-access article distributed under the terms of the Creative Commons Attribution Non-Commercial License, which permits unrestricted non-commercial use, distribution, and reproduction in any medium, provided the original work is properly cited.

## ABSTRACT

Decortication surgery is indicated in case of thickened pleural layer leading to atelectasis of the underlying lung parenchyma. It is done to prevent further restriction of the lung parenchyma. Atelectasis and collapse of lung following decortication is a common complication following the surgery. Chest physiotherapy following decortication helps in preventing the damage to the lungs and also helps in maintaining and regaining good lung function post-surgery. We present a case of right lung decortication surgery with bullectomy where various physiotherapy intervention and techniques were started early post-surgery to attain good lung expansion and prevent complications. Physiotherapy interventions like segmental breathing exercises, chest proprioceptive neuromuscular facilitation techniques, lung expansion exercises, unilateral expansion exercises, use of incentive spirometer, airway clearance techniques, resistance training and early mobilisation showed significant improvement in the chest excursion and expansion along with improved inspiratory capacity. Along with this it also helps in reducing the length of ICU (Intensive care unit) stay. Physiotherapy along with early mobilisation when started in the early postoperative period following decortications and bullectomy surgeries is useful to obtain better outcomes and shorten length of ICU stay.

**Keywords:** Chest physiotherapy, Decortication, Bullectomy, Lung expansion exercises, Unilateral lung expansion exercise, Chest PNF

## INTRODUCTION

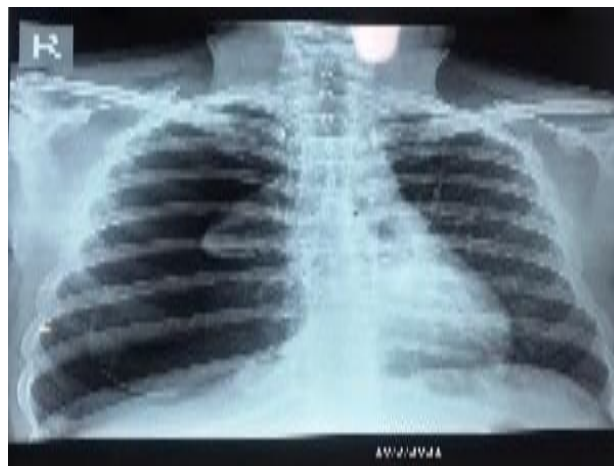
Secondary pneumothorax is a common complication following chronic obstructive pulmonary disease (COPD) due to chronic smoking.<sup>1</sup> It can also damage the lung parenchyma and the pleural layer. Chronic disease pathology can lead to fibrotic thickening of the pleural layers that may restrict the lung expansion further leading to destruction of the lung tissue. Decortication surgeries are undertaken in view of thickening of the underlying pleural layers due to chronic damage to the lungs. Thoracic decortication involves the removal of abnormally formed fibrous tissue from the pleural surfaces as well as removal of fluid, pus, or debris from the pleural space to facilitate the lung expansion. It includes the removal of thickened and fibrotic pleura that

restricts lung expansion.<sup>2,3</sup> Bullectomy is performed whenever there is an air-filled bulla detected on the chest radiograph. Most patients considered for surgery have symptoms of dyspnoea, pain, or spontaneous pneumothorax.<sup>4</sup> Physiotherapy following thoracic surgeries when initiated early have proven to be beneficial in many instances. Pulmonary rehabilitation including various physiotherapy techniques along with early mobilisation in post thoracic surgeries help in faster recovery and shorter ICU stay.<sup>5,6</sup>

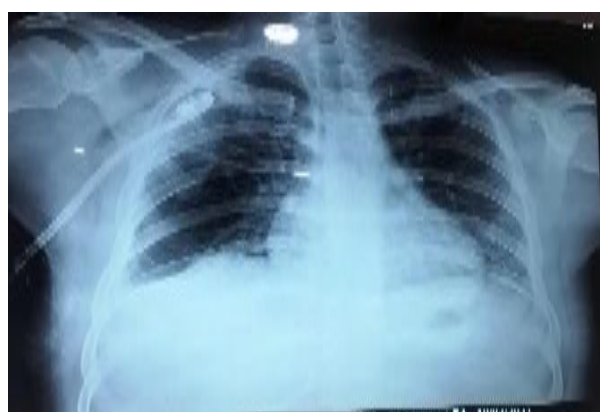## CASE REPORT

A 26-year-old male, chronic smoker for 12 years, alcoholic for 4 years, was diagnosed as a case of secondary pneumothorax on the right side with

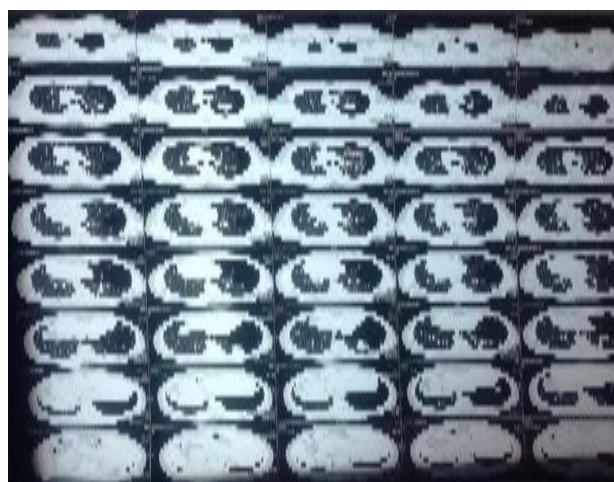
emphysematous bullae. He was treated with antibiotics and multivitamins along with ICD (intercostal drain) pigtail insertion for 12 days (Figure 2). His HRCT (High resolution computerised tomography) (Figure 3) revealed presence of multiple emphysematous bullae over bilateral lungs right more than left along with collapsed right lower segment and thickened pleura over the right lung. He was posted for decortication with bullectomy surgery. Post-surgery the patient was referred for physiotherapy. On observation the patient had undergone a right posterolateral thorotomy for decortication and emphysematous bullectomy. The patient had an ICD with column movement being present and absence of BPF (bronchopleural fistula) and a mediastinal drain in situ. He was on 4 L of oxygen via face mask maintaining the vitals of 89 bpm heart rate, saturation of 98% and respiratory rate of 28/min with a blood pressure of 128/80 mmHg. On auscultation the air entry was severely reduced over right upper, middle and lower zones, infra-axillary, infra mammary area and posteriorly all over. His chest excursion was reduced evidently over the right. His x-ray showed right pneumothorax with collapsed right lung middle and lower segments (Figure 4). He was started with chest physiotherapy session which included patient education, smoking cessation counselling and exercise sessions. The exercise sessions included manual chest percussion and vibrations along with modified postural drainage positions followed by forced expiratory techniques with splinting the suture site, assisted huffing coughing techniques, chest PNF (proprioceptive neuromuscular facilitation) for intercostals (10 reps x 2 sets each), posterior basal lift, along with apical, middle and posterior segmental tactile facilitation techniques combined with deep breathing maneuvers (10 reps x 2 sets). Segmental breathing and segmental thoracic expansion exercises for the right lung were initiated (10 reps x 2 sets). Expiratory breathing techniques using the balloon bladder, followed by deep inspiratory techniques with the help of incentive spirometer (10 repsx2-3 sets). The patient was able to generate 900cc of Inspiratory volume. Bronchial hygiene maintenance was achieved with ACBT (Active cycle of breathing technique) (2-3 cycles). Early mobilisation techniques included in-bed general mobility for bilateral upper limb and lower limb (10 repsx1 set), postural correction exercises, and edge of bed sitting was done. All the exercises were performed for 10 repetitions and 2 sets. As well as patient was advised to repeat the exercises every 4 hourly. His chest x-ray following the BD physiotherapy sessions showed good amount of right lung expansion (Figure 5) along with improved air entry on auscultation and improved chest excursion on the right side. The same protocol was followed for three days along with progression with inspiratory hold techniques for 3 sec progressed to 5 secs, incentive spirometry 1200 cc along with Inspiratory holds and progression of mobilisation to chair sitting, ambulation (40 metres progressed to 120 mts), upper and lower limb strengthening with weights (500 gm progressed to 1 kg ten repetitionsx2 sets).



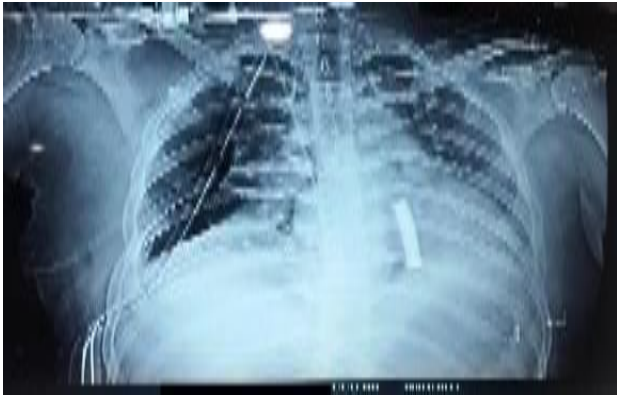**Figure 1: Chest x-ray taken on the day of admission suggestive of right sided pneumothorax with large emphysematous bullae).**



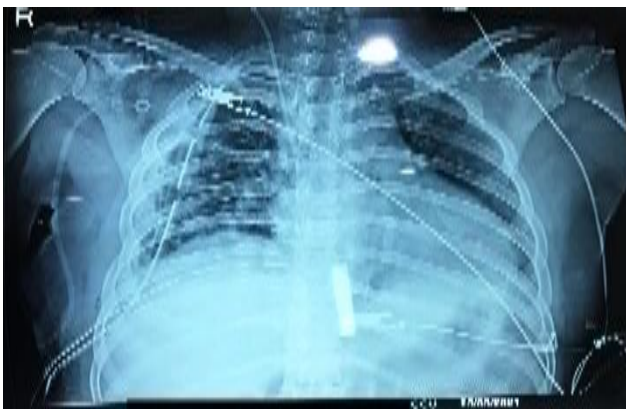**Figure 2: Chest x-ray after 12 days of ICD insertion, with pigtail in situ.**



**Figure 3: HRCT of large right sided pneumothorax with emphysematous bullae with collapsed right lower segment with pleural thickening and numerous small bullae over bilateral lungs.**

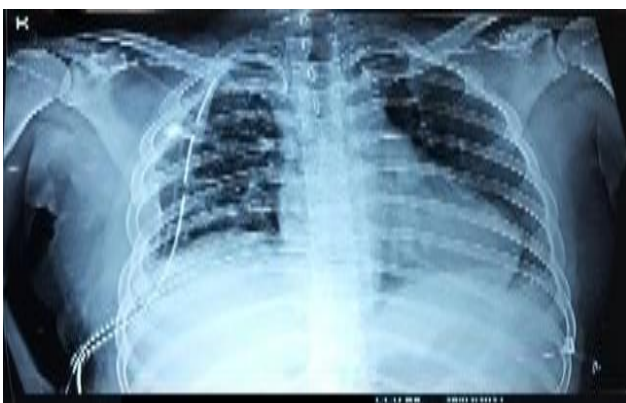

**Figure 4: Post decortication and bullectomy, right pneumothorax with collapsed lung.**

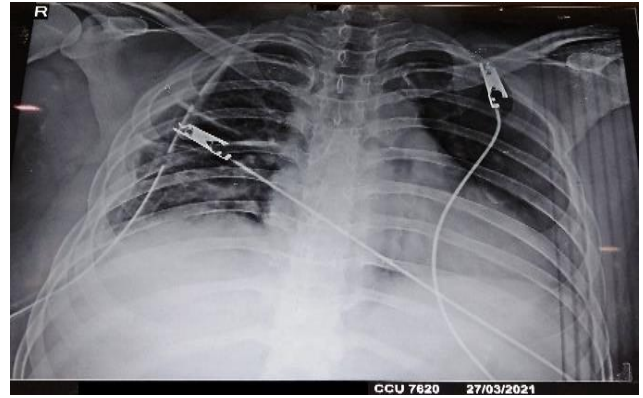


**Figure 5: Chest x-ray post physiotherapy.**

The patient was weaned off the oxygen support and was maintaining stable vitals with heart rate of 74 bpm, respiratory rate of 23 breaths/min, saturation of 99-100% and BP of 124/80 mmHg. The chest x-rays improved with better clear lung fields, near normal lung expansion was achieved (Figure 6 and 7) on the right and hence ICD was removed and the patient was shifted to the wards after 4 days of ICU stay. The sessions were continued and progressed as per the patient's capacity. The patient is currently undergoing physiotherapy rehabilitation on OPD basis.



**Figure 6: Chest x-ray of improved lung expansion.**



**Figure 7: Chest x-ray of improved lung expansion on the day of ICU discharge.**

## DISCUSSION

Atelectasis of the lung is a common complication following decortications surgery.<sup>3,7,8</sup> Chest physiotherapy plays a vital role in improving the lung expansion and regaining the lung and chest wall mobility following decortication surgery. Various chest physiotherapy techniques have been proven to be effective in improving the lung function following thoracic surgeries. The techniques of segmental breathing, ACBT, postural drainage, breathing exercise, early mobilisation, strength training, and incentive spirometry along with chest PNF and segmental facilitation techniques have proven to be beneficial post decortication surgeries.<sup>5,9,10</sup> Thus early physiotherapeutic intervention following decortication helps in improving the lung expansion and reducing the ICU stay. Post-operative physiotherapy and pulmonary if applied as a routine for thoracic surgeries following chronic lung diseases might prove helpful in further improving the outcome.<sup>6,11</sup>

## CONCLUSION

Early post-operative physiotherapy following thoracic surgeries helps in prevention of complications and hasten the process of recovery. Also starting physiotherapy in the pre-operative phase can give added benefits and help in better rehabilitation.

*Funding: No funding sources*

*Conflict of interest: None declared*

*Ethical approval: Not required*

## REFERENCES

1. Takuya O, Ueda S, Yamaoka M, Sekiya Y, Yamada H, Kawakami N et al. Primary and Secondary Spontaneous Pneumothorax: Prevalence, Clinical Features, and In-Hospital Mortality. *Can Respir J*. 2017;2017:6014967.
2. Rathinam S, Waller DA. Pleurectomy decortication in the treatment of the "trapped lung" in benign and



- malignant pleural effusions. *Thorac Surg Clin*. 2013;23:51-61.
3. Gorman J, Funk, D, Srinathan S. Perioperative implications of thoracic decortifications: a retrospective cohort study. *Can J Anesth/J Can Anesth*. 2017;64:845-53.
  4. Meyers BF, Patterson GA. Chronic obstructive pulmonary disease: Bullectomy, lung volume reduction surgery, and transplantation for patients with chronic obstructive pulmonary disease. *Thorax*. 2003;58:634-8.
  5. Baddeley RA. Physiotherapy for enhanced recovery in thoracic surgery. *J Thorac Dis*. 2016;8(1):S107-10.
  6. Batchelor TJP, Rasburn NJ, Abdelnour-Berchtold E, Brunelli A, Cerfolio RJ, Gonzalez M et al. Guidelines for enhanced recovery after lung surgery: recommendations of the Enhanced Recovery After Surgery (ERASVR) Society and the European Society of Thoracic Surgeons (ESTS). *Eur J Cardiothorac Surg*. 2019;55:91-115.
  7. Gupta AK, Sood J, Sharma S. Postoperative Complications Following Thoracic Surgery. *Clinical Thoracic anaesthesia*, Singapore Springer; 2020;1.
  8. Sengupta S. Post-operative pulmonary complications after thoracotomy. *Indian J Anaesth*. 2015;59(9):618-26.
  9. Bala N, Narwal R, Verma A. Role of Unilateral Guided Chest Expansion Technique after Decortifications in Reversing Unilateral Atelectasis. *Physiotherapy Occupational Therapy J*. 2020;13(2):67-73.
  10. Ahmad AM. Essentials of Physiotherapy after Thoracic Surgery: What Physiotherapists Need to Know. A Narrative Review. *Korean J Thorac Cardiovasc Surg*. 2018;51(5):293-307.
  11. Schwellnus L, Roos R, Naidoo V. Physiotherapy management of patients undergoing thoracotomy procedure: A survey of current practice in Gauteng. *South Afr J Physiotherapy*. 2017;73(1):a344.

**Cite this article as:** Pol TT. Effect of post-operative physiotherapy intervention following decortication and bullectomy: a case report. *Int J Res Med Sci* 2021;9:1796-9.